obstetric trauma surgery
art and science

corpus intrapelvinum
with
endopelvic diaphragm

for reconstructive pelvis surgery

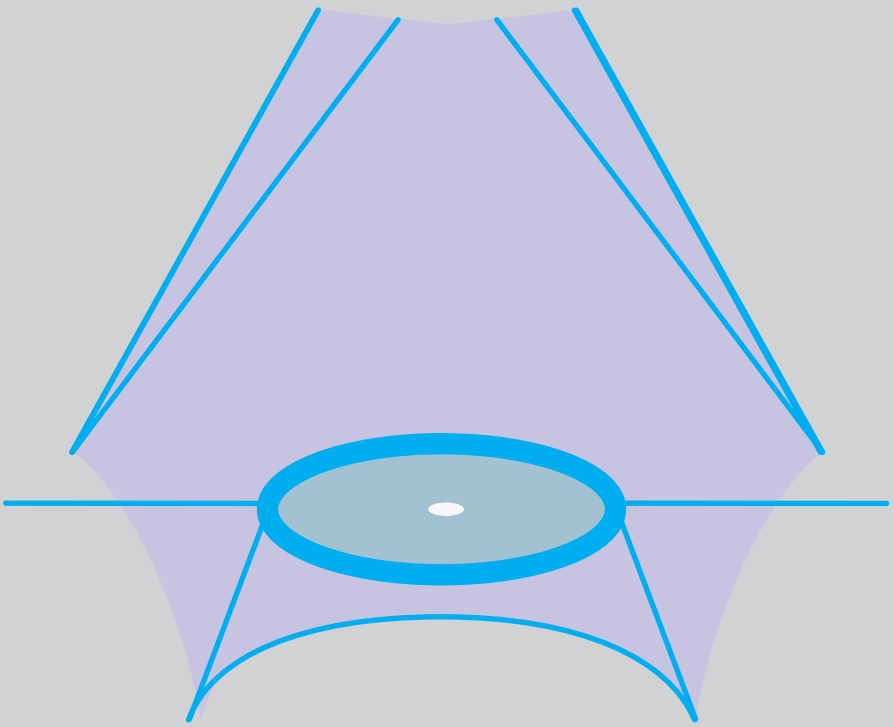

kees waaldijk

sponsored and financed by

ISBN/EAN: 978-94-90917-12-8
pages: 72
color pages: 18

drawings by the author
technical assistence by mark

national obstetric fistula center babbar ruga
katsina
n i g e r i a

obstetric trauma surgery
art and science

setting standards by evidence-based practice

corpus intrapelvinum

connective tissue body of pelvis

with

endopelvic diaphragm

decisive factor in reconstructive pelvis surgery

based on

findings and outcome

in

25,000 obstetric fistula/trauma reconstructive procedures

kees waaldijk

obstetric trauma surgery
art and science

series of textbooks each with a specific topic

setting evidence-based standards

this series has been developed for setting evidence-based standards in the training and management of the obstetric trauma in all its forms in the developing as well as in the industrialized world

the name of the series has been changed from obstetric fistula to obstetric trauma surgery since the fistula is only one aspect of the complex obstetric trauma

though a systematic approach is being followed this seems to be a utopia since the material is too extensive and it would take too long

each time a specific topic has been finalized it will be published as a separate entity; with later on an update if needed

then somewhere along the line a comprehensive summary will be produced in order to have a representative overview

the emphasis is placed on the functional anatomy of pelvis, pelvis floor and pelvis organs, the female urine and stool continence mechanisms, the mechanism of action and the principles of reconstructive and septic surgery

for training reasons it will follow a step-by-step approach and repetition; together with schematic drawings and photographs

the whole series is based on kees archives of obstetric trauma with so far 25,000 reconstructive and conservative procedures in 21,000 patients with a rare “complete” documentation of each procedure and results as to healing and continence by electronic reports with 150 parameters, over 100,000 pre/intra/postoperative digital photographs and a comprehensive database as personal experience over a 35-year period from 1984 up till now

as such it is considered to be a full scientific evidence-based report; though it has not followed the “you peer me, i peer you” doctrine

it is also not following the strict protocol of the international scientific journals or the so-called established theories; since only dead fish follow the flow of the river; and strict protocols kill any creativity; the message is not in the format

since it is the life work of the author it is written in his own words and in his own style

writing things down helps the author in organizing his own understanding and ideas

foreword

due to the **fascinating** work of halban j & talbert j in 1907 it is no wonder that the attention concerning pelvis organ position, (in)continence and prolapse shifted towards the levator ani muscles of the pelvis floor due to the **impressive** drawings

but nobody asked the real decisive question

are these defects the cause or the sequels of pelvis organ prolapse

the author is privileged to study and treat the natural experiment of the obstetric trauma in all its aspects

however, during his extensive reconstructive pelvis surgery he could neither understand the current theories nor the practices

the aim is to reconstruct the functional anatomy so that physiology will be ensured

however what he saw was that all the principles of reconstructive surgery are being violated from the incision to the end; for this one only has to look at the poor results

instead of studying the pathophysiologic mechanism of action and then find ways of reconstructing the real defects

how can that mutilating midline longitudinal vagina incision with excision of viable tissue have survived up till today against any surgical principle; how can tissue forces be so neglected and violated

and why implant **inert** artificial plastic material instead of using the available autologous anatomic structures in such a **dynamic** process as reconstructing the functional pelvis anatomy; thinking one knows it better than nature; a big mistake

so the author would like to present another concept of

corpus intrapelvinum with endopelvic diaphragm

as the main anatomic structure of stabilizing/securing the pelvis organs in their variable anatomic position and of supporting the continence mechanisms

in this textbook out of the series **obstetric trauma surgery; art and science** to outline the fundamentals of the functional pelvis anatomy in the female

which may contribute to a better understanding of the biomechanics of the pelvis cavity and its organs, the pathophysiology of incontinence and prolapse and the principles of real reconstructive pelvis surgery using the available dynamic autologous structures

kees waaldijk md phd october 2018

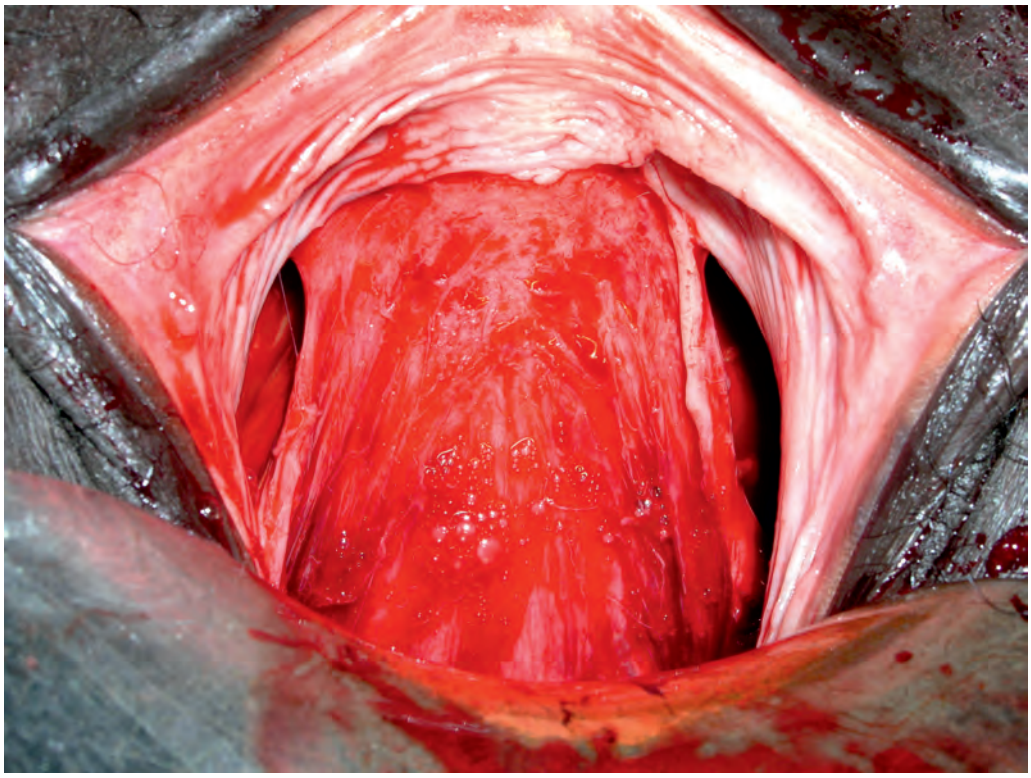

endopelvic diaphragm
pubocervical musculofascia

table of contents

introduction

Incontinence and prolapse are as old as mankind and constitute a major challenge to anybody involved

due to the work of halban and talbert 1907 and paramore 1905 the consensus about securing the organs in their anatomic position and the mechanism of (in)conti nence and prolapse concentrated upon the levator ani muscles of the pelvis floor

resulting in an enormous amount of surgical “solutions” with the strange incomprehen sive thing

that the levator ani muscles as causative culprit were hardly approached/targeted

the latest wave of consensus was implantation of artificial inert plastic materials with a severe complication rate of 20-25%; instead of using the available dynamic autologous structures which will strengthen under physiologic stress

simply because most people are more interested in tricks than in science and blinded by technology thinking they know it better than nature; a real big mistake

so right from the beginning the author wanted to know how things work and then find a solution and

after 35 years of reconstructive pelvis surgery he would like to present the

evidence-based concept of

corpus intrapelvinum
with
endopelvic diaphragm

which needs further research which is long overdue

kees waaldijk md phd october 2018

functional pelvis anatomy

essentials

true pelvis cavity
a confined space for the distal outlet organs of the urinary tract anteriorly, the genital tract in the middle and the digestive tract posteriorly with hydrostatic and compression pressure; normally in a continent way and divided into
anterior pre_subperitoneal compartment
for the distal end parts of the urinary tract: pelvic ureters, bladder and urethra
median subperitoneal compartment
for the (also distal end parts of) genital tract: uterus, adnexa, cervix and vagina
posterior retro_subperitoneal compartment
for the distal end parts of the digestive tract: rectum, anorectum and sphincter ani

enclosed by
parietal pelvis fascia covering pelvis wall/floor muscles
and
parietal peritoneum as boundary of intraperitoneal cavity
as connected to each other by
tela urogenitalis with corpus intrapelvinum and endopelvic diaphragm

corpus intrapelvinum as dynamic 3-dimensional matrix
connective tissue organ of pelvis consists of a cohesive mixture of collagen for strength, elastin for passive elasticity and plasticity and mostly smooth muscle fibers for dynamic active non-fatigue tonus in a loose, dense or condensed form as
a dynamic matrix into which the organs and their supply are embedded and suspended/ connected to the pelvis wall and each other by highly specialized structures
protecting the organs and their supply against trauma and stabilizing/securing them in their variable anatomic position
as coordinated by intrinsic myogenic impulses and the autonomic nervous system
considered to be a fluidum since no sharp demarcations between the archaic matrix and its specialized structures

endopelvic diaphragm
highly specialized structure of corpus intrapelvinum from symphysis anteriorly to sacrum posteriorly as connected to its bilateral arcus tendineus fasciae with **cervix as centrum tendineum intrapelvinum** since all musculofascia structures are connected to it
as first line of counteracting intraabdominal hydrostatic pressure and
supporting the urogenital continence mechanisms in their anatomic position and preventing herniation of the urinary tract, genital tract, intraperitoneal contents and distal digestive tract into the zero-pressure vagina

pelvis floor as one functional unit as part of abdominopelvic wall
levator ani muscles connected firmly to the perineum outlet diaphragm via perineal body and external sphincter ani muscle supporting and reinforcing each other
levator ani muscles as “pelvis diaphragm” highly overrated with direct action on stool continence mechanism and only indirect action on urine continence mechanism
perineum outlet diaphragm into which the end outlet organs with their striated sphincter mechanisms are anchored and supporting directly and the urine and stool continence mechanisms

female urine continence mechanism over in total 4-5 cm
bladder neck, uv-junction and whole urethra
supported by the endopelvic diaphragm and the perineum outlet diaphragm
there is an internal smooth muscle sphincter and an external striated rhabdosphincter with washer effect by the mucosa and submucous vascular plexus
continence potential over its whole length

female genital continence mechanism over in total 3-4 cm
with cervix as internal smooth muscle sphincter as anchored into endopelvic diaphragm

female stool continence mechanism over in total 4-5 cm
anorectum and external sphincter ani
anchored within perineum outlet diaphragm
there is an internal smooth muscle sphincter and an external striated sphincter ani muscle with washer effect by mucosa and submucous vascular plexus

urine stress incontinence mechanism genuine and post fistula repair
the anterior urethra wall is always fixed to the symphysis and cannot rotate backwards away from the symphysis whilst the posterior urethra wall is mobile as supported by the endopelvic diaphragm
once this support becomes weak the posterior urethra wall rotates backwards causing funneling = vesicalization of the proximal and mid or whole urethra with a decrease in outflow resistance so that the intrinsic closing forces can no longer counteract the intra vesical expulsion forces
or by defects within the anchoring into perineum outlet diaphragm; isolated or combined

pelvis floor muscle exercises
have a positive effect upon the urine and stool continence mechanism since
the perineum outlet diaphragm contributes to the urine and stool continence mechanism by further stabilizing the outlet parts
the levator ani muscles contribute directly to the stool continence mechanism to which they are anatomically connected but only indirectly to the urine continence mechanism with no anatomic connection whatsoever
with simultaneous reflex contraction of the external striated muscle sphincters
with increase in tonus of smooth muscle fibers of the endopelvic diaphragm by reflex action via intrinsic myogenic impulses as modulated by the autonomic nervous system

obstetric trauma
due to hydrostatic pressure, dilatation of birth canal, (in)direct cutting thru, shearing and compression; and in prolonged obstructed labor due to pressure necrosis
resulting in an enormous variety of defects from minimal to extensive

pelvis organ prolapse
herniation of adjacent high(er)-pressure organs into the zero-pressure vagina and then further prolapse thru the vagina dragging vagina wall with them as intussusception
due to defects within the separating and supporting endopelvic diaphragm structures of the corpus intrapelvinum between these organs and the vagina
levator ani muscles and perineum outlet diaphragm do not play a role in this process since there is no anatomic contact between those organs and these structures

reconstructive surgery
the science is to identify the specific defects whilst the art is to reconstruct the functional anatomy using the available dynamic autologous structures

obstetric trauma

introduction

obstetrics constitutes always a major challenge to all pelvis organs with their different structures/support and to the pelvis floor structures
and the actual trauma can be divided into two groups: lesions without and lesions with anatomic tissue loss
therefore in the first group once the lesions have been repaired and the normal ana tomy restored full function can be expected whilst
in the second group even though “normal” anatomy may be restored full function can be compromised since there is a variable amount of tissue loss

mechanism of action

there are several mechanisms by which the intrapelvic organs may be affected which will influence the functional pelvis anatomy in one way or the other

first by hormonal flooding

second by continuously increasing hydrostatic pressure due to pregnant uterus

third by dilatation of the cervix with opening up of the endopelvic diaphragm

fourth by direct or indirect cutting thru of the head thru the cervix, thru the gap between the levator ani ledges and thru the opening within the perineum outlet diaphragm

fifth by shearing forces during actual childbirth when the head passes thru the cervix, thru the vagina, thru the gap between the levator ani ledges and thru the opening in the perineum outlet diaphragm

sixth by compression with necrosis of the soft tissues between the hard fetal skull and the bony maternal pelvis

group I lesions without anatomic tissue loss

hormonal flooding

all the tissues will first “hypertrophy” to withstand the increased hydrostatic pressure and later on will soften as preparation for childbirth and will involute during the puerperium

hydrostatic pressure

since the fetus and the uterus will grow slowly there is a continuously increasing hydro static pressure which may traumatize the endopelvic diaphragm despite “hypertrophy”; in the involution phase defects may be resolved spontaneously or small defects remain whilst with subsequent pregnancies/deliveries these remaining defects may become larger up to a point where the support of the urinary continence mechanism becomes defective and/or the securing/stabilization of the organs becomes defective

dilatation of cervix with opening of endopelvic diaphragm

during the first stage of labor the cervix will efface and with it the endopelvic diaphragm will open up with possible trauma to the anchoring of the cervix into this diaphragm
when the head passes thru this opening it may further stretch/traumatize the tissues either bluntly or sharply

cut-thru trauma

when the passing of the head thru the birth canal goes too quick or when the birth canal is not fully dilated and the tissues have no time to stretch the head may cut thru the tissues either bluntly or sharply as

blunt cut-thru

in combination with stretching the bilateral ledges of the levator ani muscles may be traumatized
in combination with stretching the perineum outlet diaphragm may be traumatized resulting in a wider introitus

sharp cut-thru

when the cervix is not fully dilated the head may further traumatize the cervix and its anchoring into the endopelvic diaphragm
when the perineum outlet is too stiff the head may cut thru the perineum, sphincter ani and rectum resulting in the complex sphincter ani rupture

shifting/shearing

when the head of the infant passes thru the birth canal always shearing will take place in minor or major form
between the head and the vagina wall
between the vagina wall and the endopelvic diaphragm
between the endopelvic diaphragm and its attachment to the pubis bone and obturator internus muscle fascia and
between the arcus tendineus of the levator ani muscles and the obturator internus muscle fascia

group II lesions with anatomic tissue loss

compression trauma

when the head passes thru the vagina there will be compression of the soft tissues between the hard fetal skull and the maternal bony pelvis
normally this is not a problem during physiologic childbirth but when obstructed labor develops which is not relieved in time pressure necrosis will develop in an endless variety; from minimal to extensive anatomic tissue loss

discussion

there are always tissue changes and tissue trauma during pregnancy and childbirth even in physiologic pregnancy/labor
normally these changes/trauma will be resolved during the involution period of the puerperium though small defects may remain
repeat pregnancies/deliveries will repeatedly add to these small defects and may result in real pathologic defects
however, when labor becomes obstructed and this is not relieved in time pressure necrosis will develop resulting in an endless variety of anatomic tissue loss with devas tating consequences for the woman affected

corpus intrapelvinum

with

endopelvic diaphragm

corpus intrapelvinum

= connective tissue body of pelvis

endopelvic diaphragm

corpus intrapelvinum

multifunctional connective tissue body of pelvis

as archaic matrix

introduction

the whole complex of intrapelvic connective tissue is called the corpus intrapelvinum or connective tissue body of pelvis; as 3-dimensional matrix for the pelvis organs with their arterial blood supply, venous drainage, lymphatic drainage and innervation

it is also called endopelvic fascia or fascia endopelvina (conjugans), however, its main component consists of smooth muscle tissue/fibers; so the term fascia is misleading

though its basic anatomic structure and functions are easy to understand it is difficult to comprehend and visualize its exact anatomic extent with highly specialized functions according to the different physiologic needs

especially since there are no clear demarcations which make it difficult to demonstrate this body/organ with different structures by dissection and/or indirect imaging

however, it is only by studying its full anatomic extent and understanding its functions that progress will be made in reconstructive pelvis surgery

since weakness and defects in this important corpus intrapelvinum are responsible for the development of genuine intrinsic incontinence, urogenital prolapse, enterocele and rectocele

the amount of literature is enormous with confusing and contradicting terminology and various complicated theories

however, the anatomy and functional anatomy do not change and the author would like to give an outline as based on existing anatomic textbooks, especially

lehrbuch der topographischen anatomie as written by anton hafferl as second edition from 1957

by analyzing the topographic position in relation to the urinary and genital tract the paramount role of the levator ani muscles in these theories seems to be overvalued and highly questionable

the author thinks another concept is needed with regard to the functional anatomic urine (in)continence mechanism and pelvis organ anatomic position and prolapse

therefore he would like to introduce the concept of the endopelvic diaphragm as part of the corpus intrapelvinum as first line for counteracting the intraabdominal hydrostatic and compression pressure, as support of the urine continence mechanism and for securing the pelvis organs in their variable anatomic position; see next chapter

basics of serous membranes

the body cavities are enclosed by bones and muscles covering the bones and muscles bridging the gaps in between the bones

the **fascia interna** is the total fascia inner lining of the cavity

the **serosa** (peritoneum, pleura) is connected to this fascia by

the **tela subserosa**

depending upon the width in between the fascia and the serosa the tela subserosa may develop from minimal with its basic loose archaic texture to extensive with a cohesive mixture of collagen, elastin and smooth muscle tissue as connective tissue body/organ in a loose, dense or condensed form

the intracavity organs are embedded into the tela subserosa together with their blood supply, venous drainage, lymphatic drainage and innervation; whilst the tela subserosa also connects/suspends the organs to the cavity wall and each other

abdominopelvic cavity

the total fascia inner lining of the abdominopelvic cavity is called fascia abdominis interna; the serosa is called parietal peritoneum; the connective-tissue layer connecting the fascia abdominis interna to the parietal peritoneum is called the tela subserosa

the width between the internal fascia and peritoneum is small at the upper anterior abdo minal wall from the umbilicus upwards and at the thoracoabdominal diaphragm and the fascia interna may “fuse” with the parietal peritoneum

however, the distance between the parietal peritoneum and posterior abdominal wall, anterior lower abdominal wall and pelvis wall becomes wider and wider resulting into extensive development of the tela subserosa as tela urogenitalis

pelvis cavity

the total fascia inner lining of the pelvis cavity is part of the fascia abdominis interna; and here it is called

the fascia pelvis parietalis

the serosa is called peritoneum parietale

the tela urogenitalis is that part of the tela subserosa which is filling up the large gap between the fascia pelvis parietalis and peritoneum parietale

the intrapelvic organs are embedded into the tela urogenitalis together with their arterial blood supply, venous drainage, lymphatic drainage and innervation; whilst the tela uro genitalis also connects/suspends the organs to the pelvis wall and each other

from the tela subserosa urogenitalis 3 structures develop

fascia visceralis

encapsulating the organs and ensheathing the blood/lymphatic vessels and nerves

corpus intrapelvinum

cohesive mixture of collagen, elastin and smooth muscle tissue/fibers in a loose, dense or condensed form; its main component is **dynamic** smooth muscle tissue/fibers

loose connective tissue

filling up the spaces not occupied by the corpus intrapelvinum

fascia visceralis

as part of the tela urogenitalis which encapsulates the organs and then is named after the organ like fascia visceralis vesicae = visceral bladder fascia; and which as well ensheaths the blood and lymphatic vessels and the nerves

the space in between the fascia visceralis and the organ wall is filled up by loose connective tissue allowing the organs like the bladder to expand and deflate rapidly by filling and emptying within a short time span

when the organ does not expand and deflate rapidly like the uterus which grows slowly during pregnancy the fascia visceralis “fuses” with the organ wall and grows slowly together with the uterus; after emptying by childbirth it involutes slowly together with the uterus during the puerperium

corpus intrapelvinum = connective tissue organ of pelvis

as part of the tela urogenitalis; it constitutes a multifunctional connective tissue organ/ body and consists of a cohesive mixture of collagen, elastin and smooth muscle tissue fibers in loose, dense or condensed form according to whatever is needed

collagen for strength, elastin for passive elasticity and plasticity and smooth muscle fibers for active dynamic tonus and relaxation as coordinated by intrinsic myogenic impulses and extrinsic impulses by the autonomic nervous system

the smooth muscle component is the main component; even if some parts of it are called fascia or ligament it is still prevalent

its extensive 3-dimensional mesh-like structure ensures a seamless combination of static and dynamic functions

as a whole together with components of the organ walls as embedded into it, the corpus intrapelvinum is the major force in resisting hydrostatic and compression intraabdominal pressure due to its non-fatigue tonus which can be increased by reflex action and as such contributes to compression pressure

the pelvis floor with its large hernia-prone openings is secondary in taking care of the rest pressure

it also protects the organs with their supply from physiologic trauma during walking, sexual intercourse and childbirth

the specialized parts of it are called fasciae, septa, ligaments, plicae which all together form the corpus intrapelvinum each with a specialized function for the organs with their supply and then combined for the whole biomechanicophysiology of the pelvis cavity

it has to be considered as one multifunctional organ where the basic archaic texture has developed into individual specialized structures according to the physiologic needs

the space between one organ and another or between an organ and the adjacent cavity wall is called a spatium filled up by connective tissue in a condensed form as septum/ fascia or in a loose form or in a loose form with a thin fluid film

it embeds the organs and their arterial blood supply, venous drainage, lymphatic drai nage and innervation; and stabilizes and secures the organs in their variable anatomic position depending upon the degree of filling of the organ itself or filling of the adjacent organ(s); in whatever body position

it suspends/connects the intrapelvic organs to the pelvis wall with so called pillars for arterial blood supply, venous drainage, lymphatic drainage and innervation

it is responsible for the blood flow inside the valve-less intrapelvic veins towards the vena cava inferior

it allows the organs to expand rapidly by filling and deflate rapidly by emptying

it allows the organs to move smoothly and independently from or simultaneously with each other

depending upon the physiologic needs it condenses to dense fascia plates or septa in between the organs and ligaments from the organs to the (bi)lateral pelvis wall and also loose structures like plicae; since the ligaments are smooth muscle tissue they are called muscles a well

though it is one continuous 3-dimensional mesh-like body/organ it is subdivided into overlapping para- structures

paracystium
that part of corpus intrapelvinum into which the bladder is embedded with condensation as bladder pillar at posterior bladder base cephalad to the ischium spine containing the blood and lymphatic vessels and nerves, and the pelvic ureter; connecting/suspending the bladder to the pelvis wall

parametrium
that part of corpus intrapelvinum which embeds the uterus/cervix, tubes and ovaries with condensation as uterovaginal pillar at uterus isthmus in the frontal plane thru and cephalad to the ischium spine containing the blood and lymphatic vessels and nerves and the pelvic ureter; connecting/suspending these organs to the pelvis wall

paracolpium
that part of corpus intrapelvinum which embeds the vagina with condensation as utero vaginal pillar in the frontal plane thru and in the region of the ischium spine containing the blood and lymphatic vessels and nerves; connecting/suspending the vagina to the pelvis wall

paraproctium
that part of corpus intrapelvinum which embeds the rectum with condensation as rectum pillar caudad to the ischium spine containing the blood and lymphatic vessels and nerves; connecting/suspending the rectum to the pelvis wall

and into the condensed parts in between the organs like septum; these are not sepa rate parts but fit into the corpus intrapelvinum as part of the fascia between the organs like pubocervical musculofascia

septum vesicocervicale
in between posterior bladder and anterior cervix as vesicocervical fascia

septum vesicovaginale
in between posterior bladder and anterior vagina wall as pubocervical musculofascia

septum rectovaginale
in between anterior rectum and posterior vagina wall and is fixed to centrum tendineum perinei (perineal body) as rectovaginal fascia

the space between the septa and the visceral fascia of the organs is filled up by loose connective tissue allowing friction free movement of the organ wall against the septum; ideally this is the layer or space of interest for surgeons in bloodless dissection

spatium prevesicale
between bladder and symphysis in continuity bilaterally with

spatium paravesicale
between bladder and (bi)lateral pelvis wall
all filled up by loose connective tissue and thin adhesive fluid film allowing the bladder wall to slide against the pelvis wall and anterior abdominal wall without coming loose

spatium vesicocervicale
between bladder and cervix

spatium vesicovaginale
between bladder and vagina

spatium rectovaginale
between vagina and rectum and up to perineal body

spatium pararectale
(bi)laterally between rectum and pelvis wall in connection with

spatium retrorectale
between rectum and sacrum
continues cephalad into the spatium retroperitoneale

it reacts to hormones and reconfigures and strengthens under physiologic stress

and is subdivided into other specialized condensed structures for further stabilizing the organs and connecting them to the pelvis wall like

arcus tendineus fasciae = atf
as line of fusion bilaterally from posterior pubis bone body 0.5-1 cm from midline pubis symphysis to ischium spine; as anterolateral attachment of the endopelvic diaphragm to the pelvis wall
it is connected to the obturator fascia and to the arcus tendineus of levator ani muscle via a narrow triangular fascia sheath
inclination of 25-30° as to horizontal from anterior to posterior in upright position

pubocervical musculofascia = vesicovaginal musculofascia
in between the posterior bladder wall and anterior vagina wall as part of the **endopelvic diaphragm**; see special chapter endopelvic diaphragm

arcus tendineus of rectovaginal fascia = atrf
as line of fusion from the lateral side of perineal body over levator ani fascia to ischium spine and fuses with the posterior part of the arcus tendineus fasciae

rectovaginal musculofascia = prerectal fascia
in between the posterior vagina wall and anterior rectum wall and fixed anteriorly to the perineal body, (bi)laterally to arcus tendineus of the rectovaginal fascia and posteriorly to the cervix and the sacrouterine ligaments

vesicoumbilical fascia
in between bilateral vesicoumbilical ligaments from bladder to umbilicus

medial vesicoumbilical ligament
obliterated urachus
from median bladder to umbilicus
restricting the upward movement of the bladder

(bi)lateral vesicoumbilical ligaments
obliterated umbilical arteries
from bilateral internal iliac artery to umbilicus
restricting the upward and sideward movement of the bladder

pubovesical ligaments = pubovesical muscles
condensation of pubocervical musculofascia
stabilizing the posterior bladder neck

posterior pubourethral ligaments = pubourethral muscles
condensation of pubocervical musculofascia as anterior attachment to pubis bones
stabilizing the posterior proximal/mid urethra wall

broad ligament = parametrium from lateral uterus to pelvis wall comprising

round ligament (muscle)
smooth muscle structure from anterolateral uterus horn thru inguinal canal and radiating into labium majus and mons pubis
stabilizing uterus in anteflexion/version

infundibulopelvic ligaments = suspensory ligament of ovary
from ovary to pelvis wall
suspends ovary

ligamentum ovarii proprium = proper ovary ligament
from ovary to lateral uterus
connects ovary to uterus

cardinal ligaments
from ilium/ischium bones to (bi)lateral cervix in a frontal plane cephalad to the ischium spines
suspending/connecting the cervix and endopelvic diaphragm bilaterally to the pelvis wall

sacrouterine ligaments = rectouterinus muscles
from cervix to rectum and sacrum
attached to (ischio)coccygeus fascia and piriformis fascia via fascia sheath

endopelvic diaphragm

one highly specialized structure within the corpus intrapelvinum as a whole constitutes a dynamic functional endopelvic diaphragm; see next chapter

loose connective tissue

as part of the tela urogenitalis in a loose archaic form filling up the spaces not occupied by the corpus intrapelvinum; these spaces are of interest to the surgeon for a bloodless dissection

this allows friction-free movement/sliding of the organ wall against the structures of the corpus intrapelvinum without becoming loose from each other

and together with a thin adhesive fluid film it allows the bladder wall to slide against the anterior abdominal wall and anterior and lateral pelvis wall without becoming loose

and ensuring that the anterior urethra wall is always adherent to the posterior symphysis and as such does not rotate; not even if the posterior urethra wall rotates backwards away from the posterior symphysis due to defective connective tissue support and then resulting into progressive funneling or vesicalization of the urethra starting proximally

innervation

the corpus intrapelvinum is controlled and coordinated by **intrinsic** myogenic impulses via baro- and stretch receptors as modulated by **extrinsic** impulses from the autonomic (sympathetic, parasympathetic ?and also enteric?) nervous system via a complex reflex mechanism and from hormones and from other neurotransmitters

since its main component is smooth muscle tissue/fibers the corpus intrapelvinum forms a highly dynamic body/organ due to its non-fatigue tonus and has the ability to react by hypertrophy and hyperplasia for increased strength; and also by involution

discussion

how to describe an important 3-dimensional mesh-like collagen, elastin and smooth muscle connective tissue organ without clear demarcations in its full anatomic extent and full **dynamic** multi-functionality as

a combination of a synchronized **multi-unit** smooth muscle archaic matrix with **single-unit** smooth muscle specialized structures with **tonic action** for non-fatigue tonus and immediate superimposed reactive **phasic action** upon stretch

with a stop anteriorly at the umbilicus and continuous with the tela subserosa of the retroperitoneal space posteriorly cephalad since both belong to the tela subserosa of the whole abdominopelvic cavity

as based on findings during his obstetric trauma surgery and evidence based results it became clear that another concept was needed; as one major function of the corpus intrapelvinum

the problem is that since there are no clear demarcations between this body and the organs except for the visceral organ fascia and between the different structures of the corpus intrapelvinum like a **fluidum** it is difficult to demonstrate it as a whole and/or demonstrate its different structures by surgical dissection and/or indirect imaging

however, once one starts looking for this dynamic corpus and its different structures as a surgeon one will find it and its structures and then starts realizing its paramount importance for the functional pelvis anatomy

though the different structures have their own specific function their actual strength is that their function will be reinforced by the simultaneous function of the whole corpus intrapelvinum as one dynamic biomechanicophysiologic unit

embedding the organs and their arterial blood supply, venous drainage, lymphatic drai nage and innervation and being

responsible for the independent physiologic functioning of the organs, for stabilizing/ securing the organs in their variable anatomic position, for suspending/connecting the organs to the pelvis wall and to each other, for protecting the organs and their supply against physiologic trauma during walking, sexual intercourse and childbirth and for supporting the continence mechanisms of the urinary, genital and digestive tract

genuine intrinsic urine incontinence, urogenital prolapse like cystocele and uterus/cervix prolapse, intraperitoneal content prolapse like enterocele and digestive prolapse like rectocele are all due to localized defects in the endopelvic diaphragm of the corpus intrapelvinum; in isolated form or combined

though the author believes strongly in this concept, time and evidence-based results and challenges by other reconstructive surgeons will tell if he is right or wrong

first edition november 2015

last edition october 2018

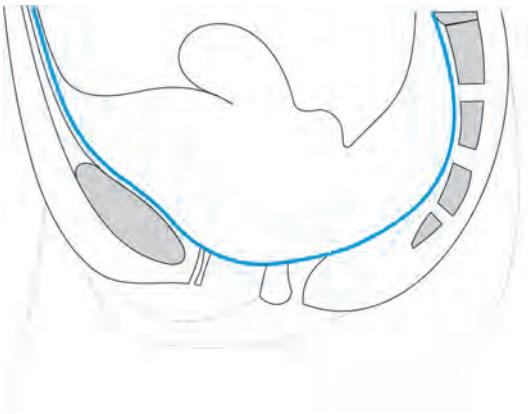

fascia pelvis parietalis

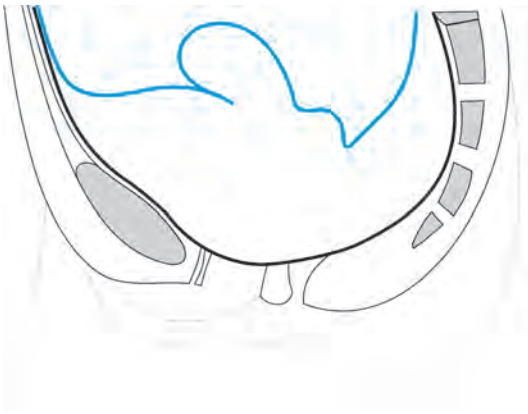

peritoneum parietale

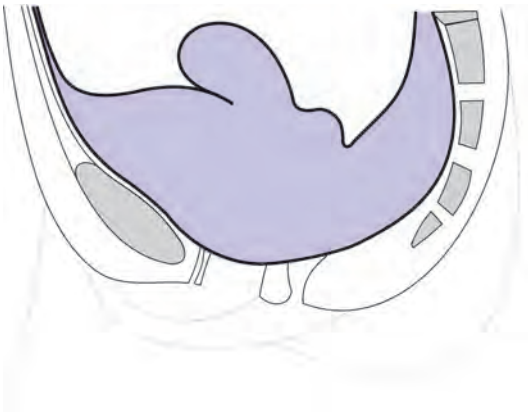

tela urogenitalis

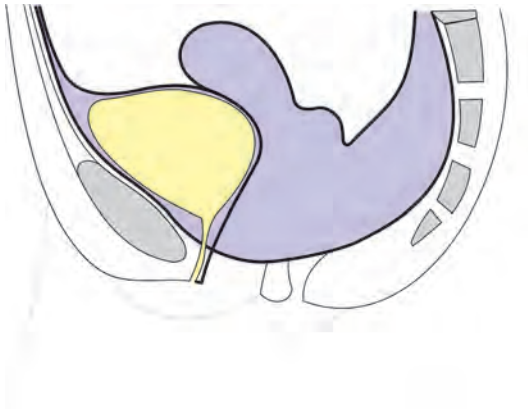

urinary tract compartment

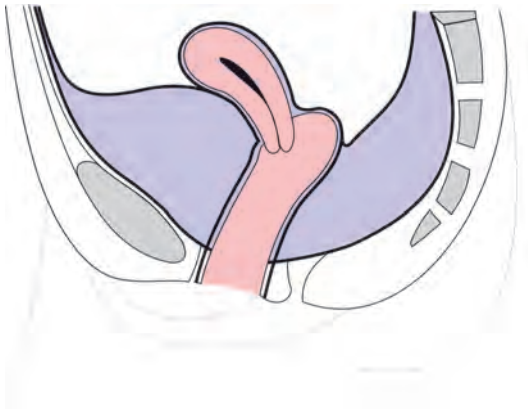

genital tract compartment

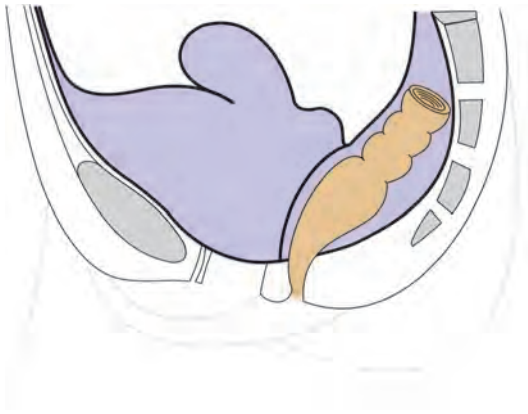

digestive tract compartment

endopelvic diaphragm

in the female

with cervix as its central point

introduction

the intrapelvic organ and organ support situation in the female differs radically from the situation in the male by the interposition of the large female genital tract in between the distal urinary tract anteriorly and the distal digestive tract posteriorly

all embedded into the corpus intrapelvinum of the tela urogenitalis, together with their vascular and nervous supply

though the situation of the superior layer of pelvis floor is more or less the same since the levator ani muscles are not affected; except for a wider pelvis

the perineum outlet diaphragm is severely weakened by the large vagina opening; so instead of two now a third and large opening has been pierced thru punched out

so the pelvis floor in the female is prone to dysfunctioning

there is increased hydrostatic intraabdominal pressure due to the weight of the female genital organs; especially during pregnancy

also the support of the anatomic female urine continence mechanism changed since in the male it is well supported by the prostate

as compensation in order to support the female bladder and urethra and the uterus and cervix and to withstand the intraabdominal pressure the corpus intrapelvinum formed a functional dynamic structure as the author would like to call the

endopelvic diaphragm

from the pubis bone bodies anteriorly to the sacrum posteriorly and circumferentially connected to the pelvis wall like the skin of a drum or trampoline with the cervix as its center; and fusing anteriorly with the perineum outlet diaphragm under an angle of 35-40°

in between the distal urinary tract, the proximal genital tract, the intraperitoneal contents and the distal digestive tract and the vagina

with a small opening anteriorly for the urethra and a larger one posteriorly for the rectum

since the cervix is firmly anchored into the central pierced thru punched out opening it becomes the centrum tendineum intrapelvinum as well; since all the musculofascia structures are firmly anchored onto it

it consists of a mixture of connective tissue for strength, elastin for passive elasticity and plasticity and smooth muscle fibers for active dynamic non-fatigue tonus and relaxation via baro- and stretch receptors as modulated by the autonomic nervous system

it is the first line of counteracting the hydrostatic intraabdominal pressure and contri butes to compression pressure by increase or decrease of its tonus; especially since its main component is smooth muscle fibers

whilst the rest pressure is dealt with by the pelvis floor structures, especially by the perineum outlet diaphragm

it supports the posterior urethra, posterior uv-junction and posterior bladder neck in their anatomic position and as such contributes to the anatomic urine continence mechanism

it prevents the posterior urethra, posterior bladder, cervix, intraperitoneal contents and anterior rectum from herniating into the vagina

it is divided into specialized parts as the pubovesical/posterior pubourethral ligaments, pubocervical musculofascia, arcus tendineus fasciae, cardinal and broad ligaments, rectovaginal fascia and sacrouterine ligaments with the cervix as centrum tendineum intrapelvinum since all its musculofascia/ligament structures are firmly connected to it

pubovesical/posterior pubourethral ligaments (= muscles)
anchoring the most anterior part of the pubocervical musculofascia as part of the endo pelvic diaphragm onto the pubis bone bodies and

securing the posterior proximal urethra, uv-junction and bladder neck in their anatomic position and so supporting the female urine continence mechanism

once they become defective intrinsic stress incontinence may develop

pubocervical musculofascia
like a triangle from the pubis bone bodies and bilateral atf to the cervix as the anterior part of the endopelvic diaphragm as part of the corpus intrapelvinum

this thick musculofascia is well developed and seems to consist of longitudinal smooth muscle/collagen fibers (from anterior towards posterior) and underneath the mid/distal urethra also transverse smooth muscle/collagen fibers (in between the median inferior surfaces of the pubis bones) interwoven by collagen and elastin

the longitudinal arrangement seems likely since longitudinal median defects are found intraoperatively at genuine incontinence, cystocele and cervix prolapse surgery

the anterior transverse arrangement seems likely since the median longitudinal defects stop at 1.5-2 cm to the external urethra opening where <u>the endopelvic diaphragm fuses with the perineum outlet diaphragm</u>

the intact pubocervical musculofascia secures and stabilizes the (posterior) bladder base/neck, uv-junction and urethra in their anatomic position and as such supports the female urine continence mechanism; it also stabilizes the cervix anteriorly and bilaterally

the intact pubocervical musculofascia prevents the pre/subperitoneal contents bladder base/uv-junction/urethra and the cervix from herniating into the vagina

the **axis** of the pubocervical musculofascia as to the horizontal/ground is 25-30° from symphysis to ischium spine in the upright position

the posterior wall of the urethra, uv-junction and the bladder trigonum are not expanding during the asymmetric filling of the bladder; therefore these structures are firmly fixed to the pubocervical musculofascia/endopelvic diaphragm whilst

the anterior vagina wall is rapidly expanding and deflating with shearing during sexual intercourse and even more during childbirth and as such is loosely connected/fixed to the pubocervical musculofascia/endopelvic diaphragm

arcus tendineus fasciae = atf
as bilateral fixation/insertion of the endopelvic diaphragm/pubocervical musculofascia whilst

the arcus tendineus fasciae is further connected to the lateral pelvis wall (arcus tendi neus of levator ani muscle and oburator internus muscle fascia) via a narrow triangular fascia sheath

cervix
the cervix is considered to be the centrum tendineum intrapelvinum since all musculo fascia structures of the endopelvic diaphragm are firmly anchored onto it and the cervix itself is firmly anchored into the central pierced thru punched out opening within the endopelvic diaphragm

cardinal ligaments and broad ligaments
since their smooth muscle fibers radiate into the cervix they support the endopelvic diaphragm restricting its downward movement

sacrouterine ligaments = rectouterinus muscles
as posterior fixation of the endopelvic diaphragm onto the sacrum since they fix/connect the cervix posteriorly onto the rectum and sacrum restricting its anterior movement

with lateral fixation to the pelvis wall (coccygeus muscles, sacrospinous ligaments and priformis muscles) via fascia sheaths

they contract during childbirth keeping the cervix in its position by preventing upward movement

(part of the) rectovaginal fascia
In between the vagina and rectum and anchored onto the posterior cervix in between the sacrouterine ligaments as part of the endopelvic diaphragm

weakest point in endopelvic diaphragm/pubocervical musculofascia
considering the anterior cone-like triangular shape with the narrowest at the pubis bones and the broadest in between the ischium spines the weakest point is in the median at the anterior cervix

and the **broader the pelvis** (with broad span) the **more prone for median defects** and as such for stress incontinence, urethrocele, cystocele and cervix prolapse

innervation

by **intrinsic** myogenic impulses
from baroreceptors for **tonic** action for a long-standing non-fatigue tonus to counteract the intraabdominal hydrostatic pressure and from stretch receptors for an immediate **phasic** action upon stretch on sudden intraabdominal pressure rise as superimposed upon the already existing tonic action

as modulated

by **extrinsic** impulses
from the autonomic nervous system via complex mechanism of reflex action and from hormones and from other neurotransmitters

it is very well possible that there are also impulses from the enteric nervous system

mechanism of physiologic action

the endopelvic diaphragm is a **single-unit** smooth muscle structure with **tonic** action for a non-fatigue tonus to counteract the hydrostatic pressure and immediate reactive **phasic** action by contraction upon stretch as superimposed upon the tonic action to counteract sudden intraabdominal pressure rise, like cough, standing up etc

this in combination with the synchronized **multi-unit** archaic matrix of the corpus intra pelvinum with its other **single-unit** smooth muscle specialized structures

and as such stabilizing/securing the pelvis organs in their variable anatomic position and supporting the continence mechanisms

especially preventing the posterior bladder neck, posterior uiv-junction and posterior urethra wall from backward rotation with funneling of the urethra

this explains the fact that even under spinal anesthesia and with a filled bladder a sudden fist push onto the suprapubic lower abdominal wall combined with coughing does not result in urine loss thru the euo (as stress incontinence) when the endopelvic diaphragm is intact

this test is a standard procedure to check continence during all our reconstructive pelvis surgery

reaction to biomechanic stress and hormones

during pregnancy there is continuously increasing intraabdominal hydrostatic pressure combined with hormonal flooding

since smooth muscle cells are also capable to multiply if the need arises the endopelvic diaphragm will then react by hypertrophy and hyperplasia according to the increasing intraabdominal hydrostatic pressure and hormones

during the puerperium the endopelvic diaphragm will involute as well according to the decreasing intraabdominal hydrostatic pressure until an equilibrium has been achieved

nb the decrease of estrogens in the second half of the cycle may explain the fact that the symptoms of stress incontinence may worsen during the second half of the cycle

mechanism of pathophysiologic action

the downward intraabdominal pressure upon the endopelvic diaphragm may lead to defects within this diaphragm

the downward pressure increases during the course of pregnancy with highest pressure at the median where the cervix is anchored into the endopelvic diaphragm

the broadest part of the endopelvic diaphragm is in between the ischium spines where it stabilizes and secures the cervix and

this is exactly where splitting/division of the longitudinal smooth muscle/collagen fibers at the median starts and then continues from proximally to distally whilst

the endopelvic diaphragm fibers retract bilaterally since medially disrupted

normally the most distal 1-2 cm stay intact since the short span is able to withstand the pressure and the smooth muscle/collagen fibers are also transverse (and longitudinal)

it is good to remember that during childbirth itself the pressure changes from downward caudad to upward cephalad and that semicircular compression and shearing occur at where the endopelvic diaphragm is attached to pubis bone and atf

in prolonged obstructed labor pressure necrosis may develop and lead to anatomic tissue loss defects at any location within the endopelvic diaphragm

then there may be direct trauma (penetration, surgery) and trauma due to infection

defects within the endopelvic diaphragm

there are two types of defects viz defects **without** anatomic tissue loss like those due to intraabdominal pressure or shearing and defects **with** anatomic tissue loss varying from minimal to (sub)total loss like those due to pressure necrosis in prolonged obstructed labor or due to infection or due to surgery

aa defects without anatomic tissue loss

since it is the first line of withstanding intraabdominal hydrostatic pressure especially during pregnancy and also withstanding shearing forces during sexual intercourse and physiologic vaginal childbirth

it is clear that defects may develop weakening the endopelvic diaphragm in varying degrees from minor to extensive

it is good to realize that during pregnancy the direction of long-term pressure is from cephalad to caudad whilst during childbirth the short-term pressure is from caudad to cephalad upon this diaphragm

since it has multiple functions, like supporting the urine continence mechanism and securing the organs in their anatomic position, defects within the diaphragm will have different effects depending upon their location

the possibilities are as following: anterior, median, lateral, central and posterior; isolated or in any combination

anterior defects
with weakening of the urine continence support since the posterior urethra wall will "rotate backward" away from the symphysis causing vesicalization of the (proximal) urethra since fixed/adhesive anterior urethra wall
by this mechanism genuine or postrepair intrinsic stress incontinence develops

median longitudinal defects
depending upon its location the posterior urethra, bladder base may herniate thru this defect into the zero-pressure vagina and eventually prolapse to the outside
only if there is also concomitant weakening of the support or dorsal-directed pull on the posterior urethra wall towards the sacrum the urine continence mechanism may be involved

central defect
the cervix/uterus will herniate thru this defect into the vagina and then may prolapse unopposed to the outside thru the hernia-prone opening in the pelvis floor dragging the anterior vagina wall with it like intussusception
only infrequently if there is concomitant weakening of the support or dorsal-directed pull on the posterior urethra wall towards the sacrum the urine continence mechanism may be involved
normally there is full urine continence in total uterus/cervix prolapse c3 or c4 even with a urethra length of only 0.5-1 cm
however, with increased longitudinal bladder diameter, shortened urethra and narrow external urethra opening

apical defect
this will result in herniation of the intraperitoneal contents into the zero-pressure vagina

posterior defects
this will result in herniation of the rectum into the zero-pressure vagina especially when combined with perineal body defects

lateral defects at atf
this will result in loss of tonus of the endopelvic diaphragm and increase in the caudad/cephalad movements but not in herniation/prolapse of an organ thru this defect

lateral defects of the fascia sheath in between the atf and atlam
this will result in medial displacement of the atf with loss of tonus and hypermobility of the endopelvic diaphragm but not in herniation/prolapse of an organ thru this defect

other location
due to penetrating trauma or forceps delivery or vacuum delivery

bb defects with anatomic tissue loss

it is good to realize that in any obstetric urine fistula there is anatomic tissue loss of the endopelvic diaphragm/pubocervical musculofascia as well

therefore in obstetric trauma surgery one should make an effort to identify the musculo fascia defects and repair them together with the fistula

the extent and location of pressure necrosis lesions in prolonged obstructed labor may be from minimal to extensive and from one location to the other in an endless variation which makes the obstetric trauma so intriguing

circular punched out defects
the same size as the fistula or (slightly) bigger than the fistula

transverse curved defects
bigger than the fistula whereby the fistula is somewhere within this defect

quartercircular defects
with partial or total anatomic loss of atf and atlam and possible partial loss of levator ani muscles, obturator muscles and obturator membrane
with fistula formation and possible opening of the paravesical space

semicircular defects
with partial or total anatomic tissue loss of atf and atlam; and with partial tissue loss of the levator ani muscles, obturator internus muscles and obturator membrane; eventually with bare bones
with fistula formation and opening of the paravesical space

(sub)total pubocervical musculofascia loss
regularly (sub)total fascia loss with extensive fistula formation and anterior vagina wall loss and total loss of atf and atlam and (partial/extensive) loss of levator ani muscles, obturator internus muscles and obturator membranes is found with bare bones in a so-called **empty pelvis**

(sub)total endopelvic diaphragm loss
from time to time (sub)total loss of the whole diaphragm may be found with extensive soft tissue loss resulting in extensive urine/stool fistulas as cloaca; for these unfortunate women nothing can be done

however, anatomic tissue loss may also be found

due to **surgery** whereby tissue is excised

or due to **necrotizing infections** like postmeasles noma vaginae

cc combination of functional with anatomic defects

this combination of **aa** and **bb** is always possible and has to be checked for during the reconstructive procedure

reconstructive surgery

it is important first to identify the real (extent of the) defect(s) and then reconstruct the functional anatomy meticulously using autologous structures so that normal physiology will be ensured whilst

special attention has to be given to check that all (musculo)fascia structures are firmly (re)connected to the cervix as the centrum tendineum intrapelvinum

discussion

the endopelvic diaphragm as part of the corpus intrapelvinum is an important dynamic structure

it constitutes a real diaphragm with the cervix as its center with a small anterior median opening for the urethra and a larger posterior median opening for the rectum

separating the distal urinary tract, proximal genital tract, intraperitoneal contents and distal digestive tract (rectum) from the zero-pressure vagina

counteracting as first line the intraabdominal hydrostatic pressure due to the non-fatigue dynamic tonus of its smooth muscle component by its tonic action via baroreceptors as modulated by the autonomic nervous system; whilst the rest pressure is then dealt with by the pelvis floor structures

with immediate reactive phasic action contraction upon stretch as superimposed upon the already existing tonic action in case of sudden intraabdominal pressure rise

contributing to securing and stabilizing the pelvis organs in their variable anatomic position and as such

supporting the anatomic urine and genital continence mechanisms

defects in this diaphragm are rather common and may be due to (increased) hydrostatic pressure, shearing by vaginal childbirth, pressure necrosis during prolonged obstructed labor, penetrating trauma and necrotizing infection; as also influenced by hormonal and ageing processes

depending upon (the large variety of) the anatomic location and extent of these defects the following is possible

intrinsic stress incontinence, ?cervix incompetence?, urethrocele, vesicocele, uterus/cervix prolapse, enterocele and rectocele; either isolated or in combination

there is a clear correlation between genuine intrinsic urine incontinence, cystocele and cervix prolapse with a wide pubic arch of $\geq$ 90° as indication of a wide pelvis

simply since the wider the pelvis the broader the span by the diaphragm and the more chance the longitudinal fibers will split/divide in the midline; with its weakest point just anteriorly from the cervix where the span is the widest

though lateral defects due to hydrostatic pressure and/or shearing at atf level and lateral defects in the narrow triangular fascia sheath between atf and atlam are possible this will not lead to herniation of the posterior bladder wall thru these defects into the vagina

at least the author has not encountered this as the cause of cystocele; the only time the author encountered a lateral defect with cystocele formation was in a patient who developed a fourth obstetric fistula after successful repair of three previous obstetric fistulas including an extensive type **IIBb**

in quartercircular and semicircular defects (always combined with lateral defects) with anatomic tissue loss of the endopelvic diaphragm and with fistula formation ensuring an empty bladder, another mechanism comes into play according to the natural tissue forces; besides the fact that the urethra and bladder will retract in opposite directions

which is the opposite of what one would expect

due to the balloon-like structure of the bladder with anterior bladder wall adherent/sticking to the posterior symphysis this will result in anterior and cephalad pull onto the posterior bladder (neck) wall whereby the loose endopelvic diaphragm is pulled as well and will re-attach onto the pubis bones and bilateral pelvis wall at a more anterior and cephalad level due to the natural tissue forces

actually, the saucer-like shape of the empty bladder in the normal anatomic situation is caused by the fact that the fixation of the posterior bladder wall onto the endopelvic diaphragm prevents the natural tissue forces from adapting the posterior bladder wall onto the anterior bladder wall

in identifying the endopelvic diaphragm
look for
shiny smooth muscle tissue

first edition january 2005

last edition october 2018

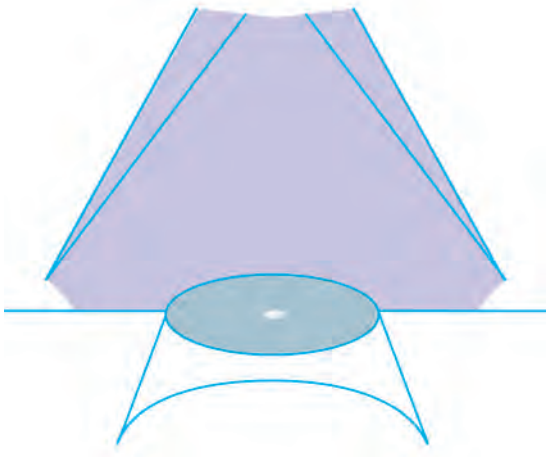

pubocervical fascia

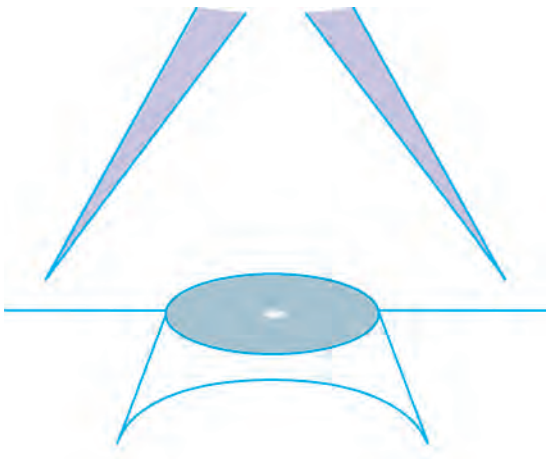

fascia sheath atf/atlam

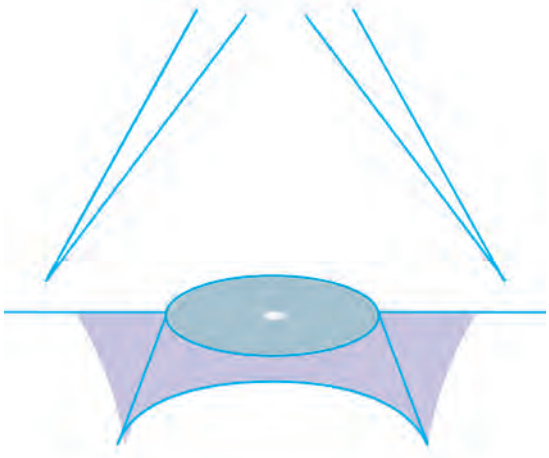

rectovaginal fascia

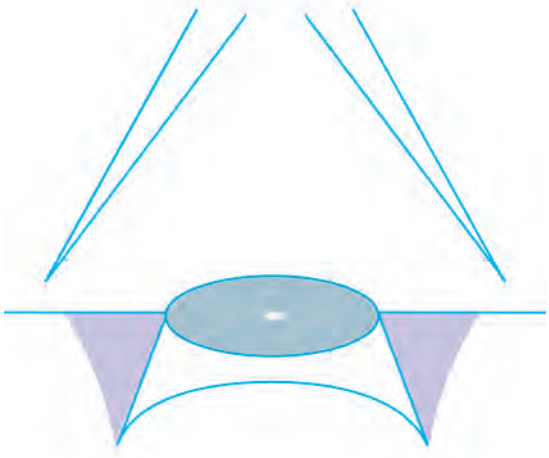

lateral fascia attachment

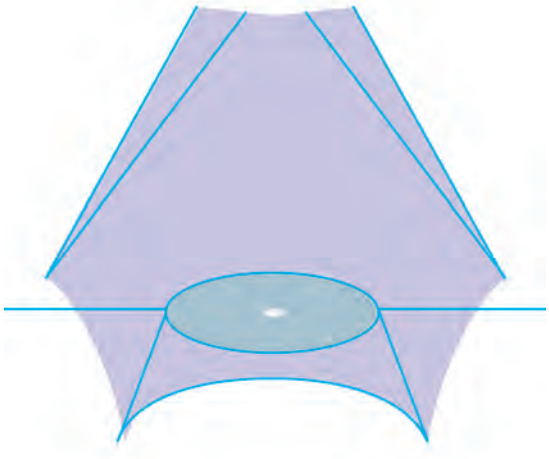

endopelvic diaphragm

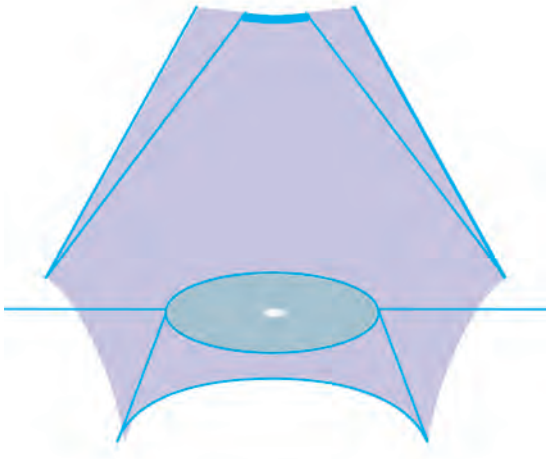

endopelvic diaphragm
posterior pubourethral ligaments

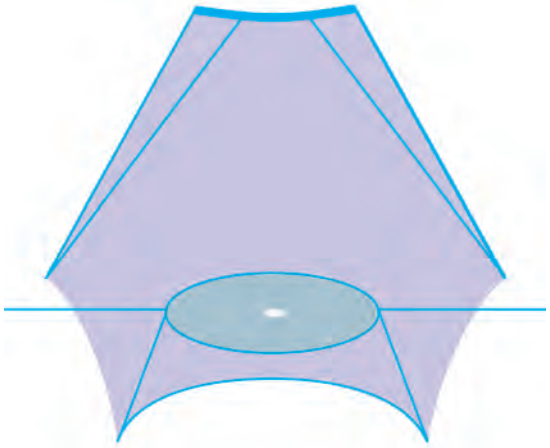

endopelvic diaphragm
pubovesical ligament = muscle

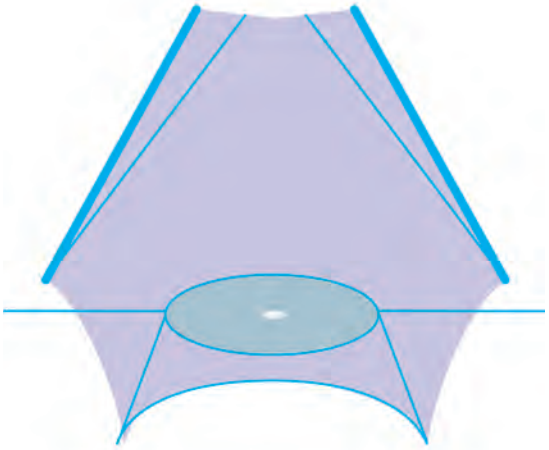

endopelvic diaphragm
atlam

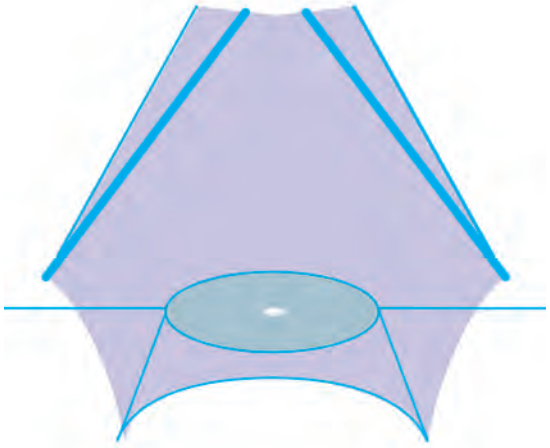

endopelvic diaphragm
atf

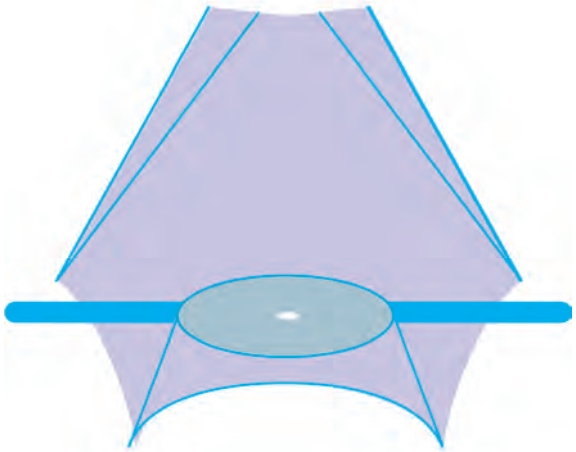

endopelvic diaphragm
cardinal ligaments

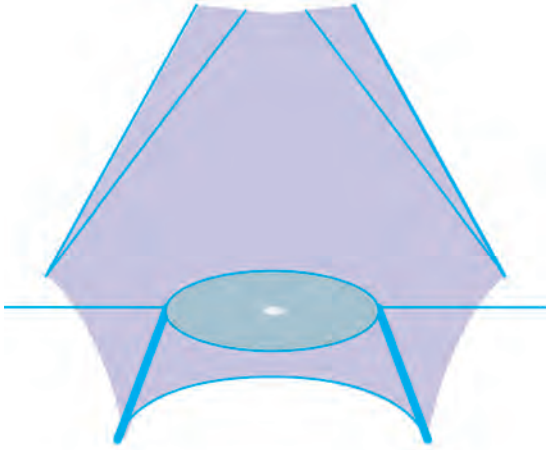

endopelvic diaphragm
sacrouterine ligaments

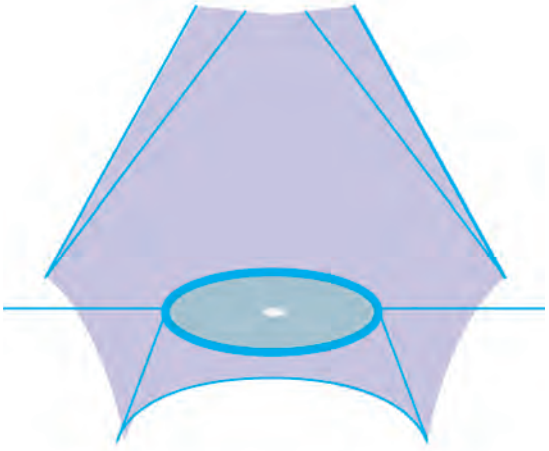

endopelvic diaphragm
centrum tendineum intrapelvinum
with fascia anchoring

physiologic incision

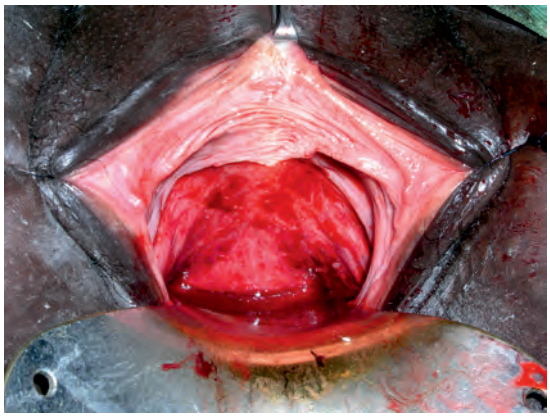

dissection

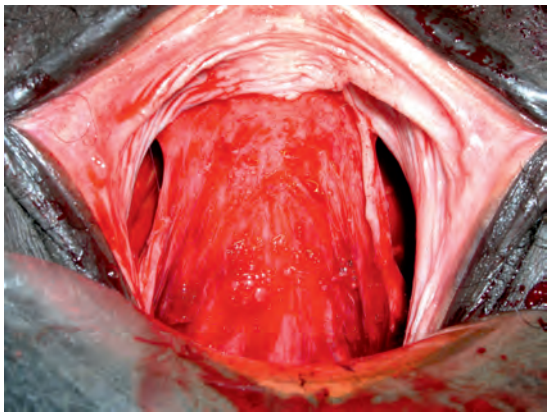

pubocervical fascia
longitudinal fibers

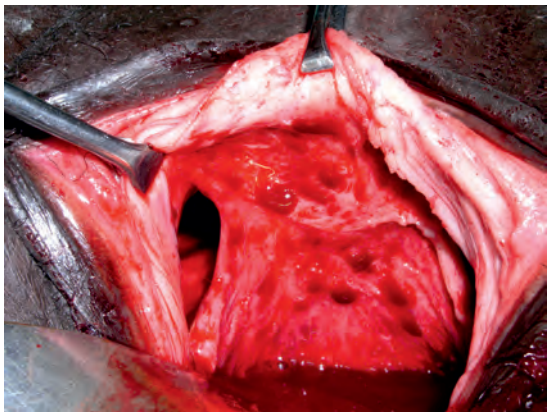

paravesical space right
transverse fibers
underneath urethra

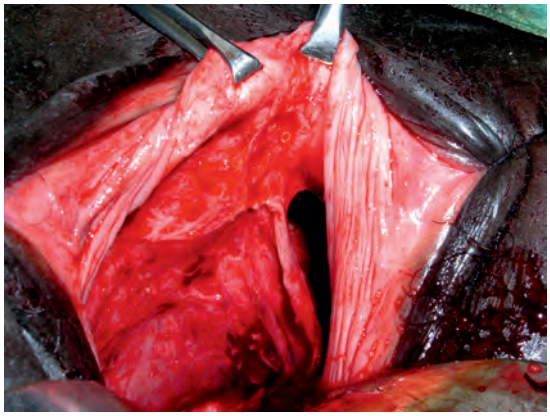

paravesical space left

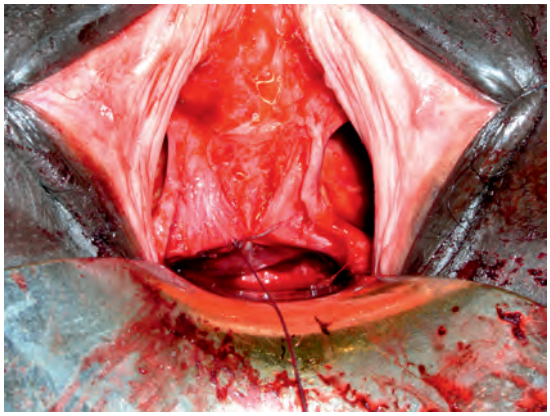

median fascia defect

cervix anchoring

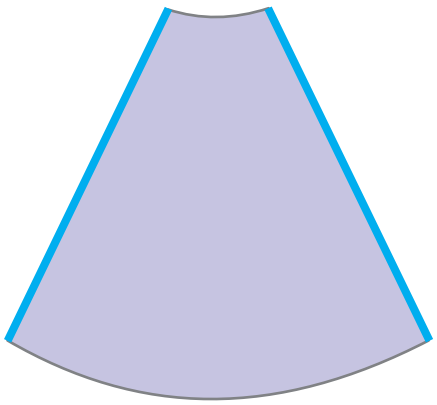

pubocervical musculofascia

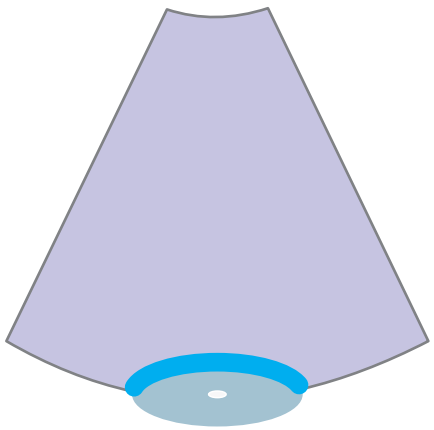

anterior cervix fixation

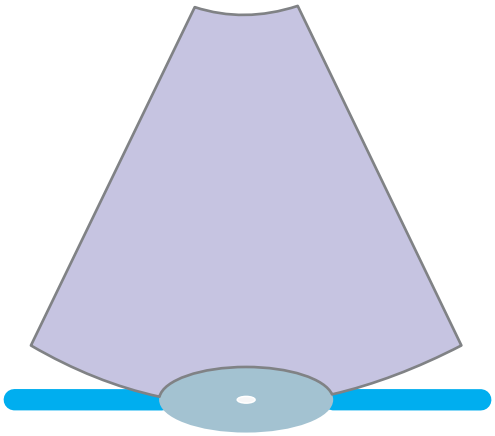

lateral cervix fixation
broad and cardinal ligaments

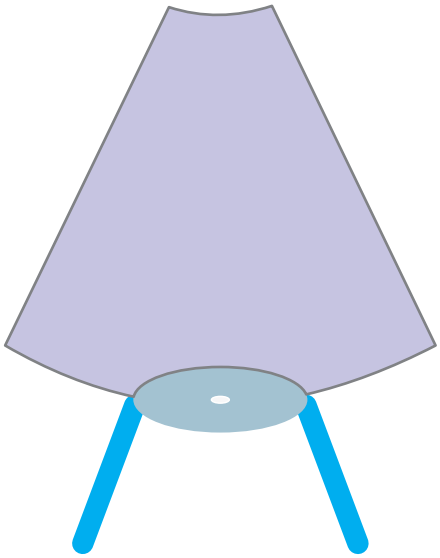

posterior cervix fixation
sacrouterine ligaments

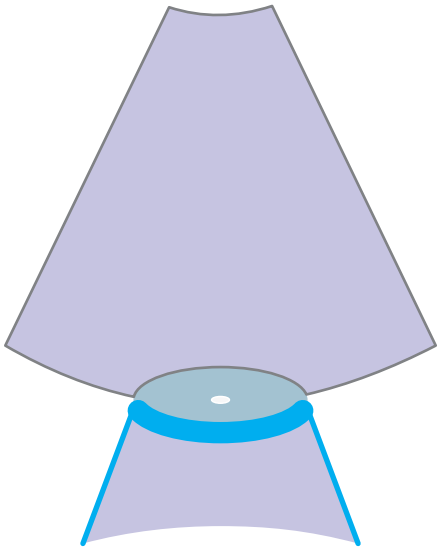

posterior cervix fixation
rectovaginal fascia

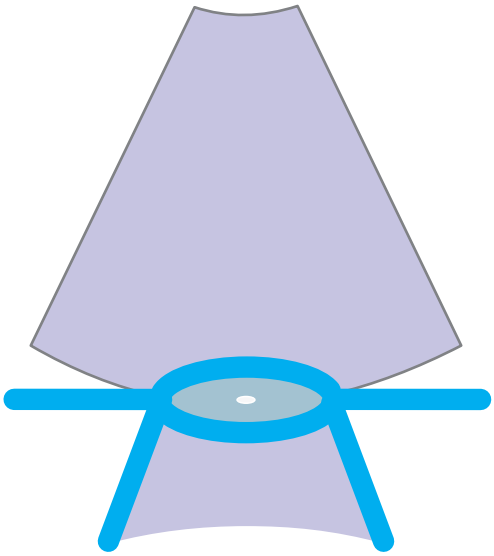

total cervix fixation

incision anterior vagina wall

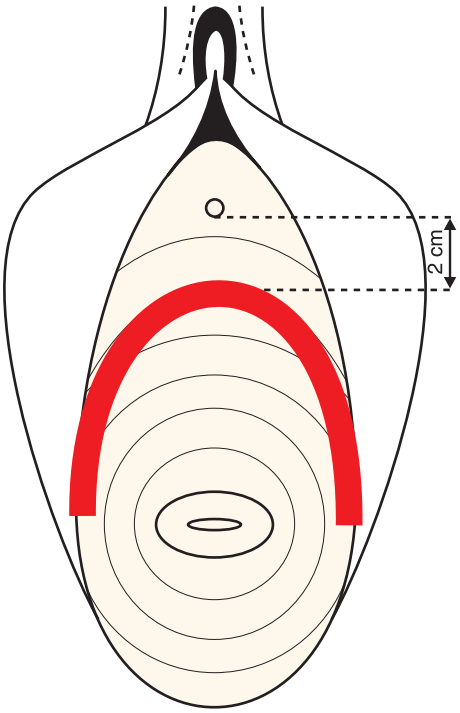

physiologic incision

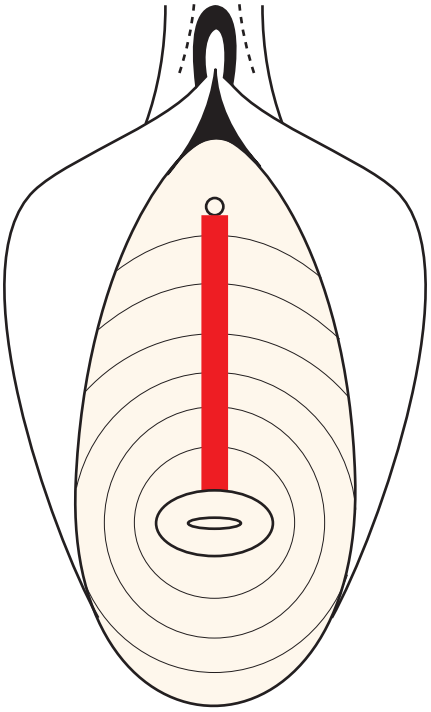

mutilating incision

trauma endopelvic diaphragm

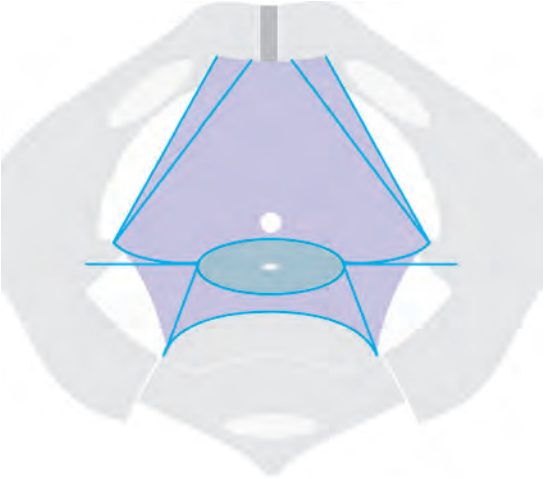

small anterior trauma

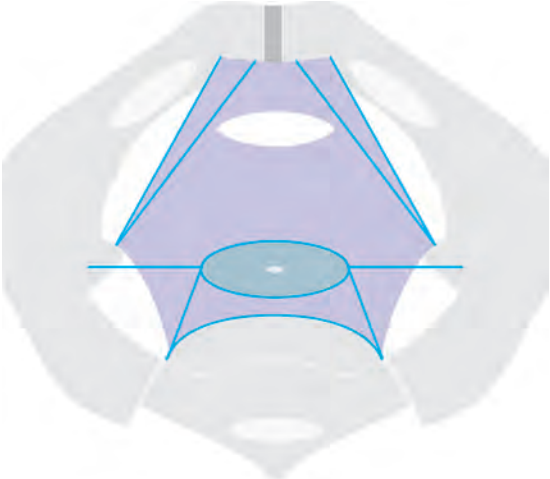

transverse trauma

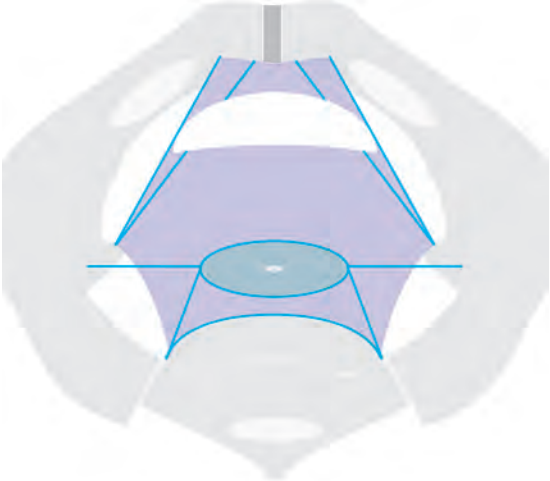

quartercircular trauma

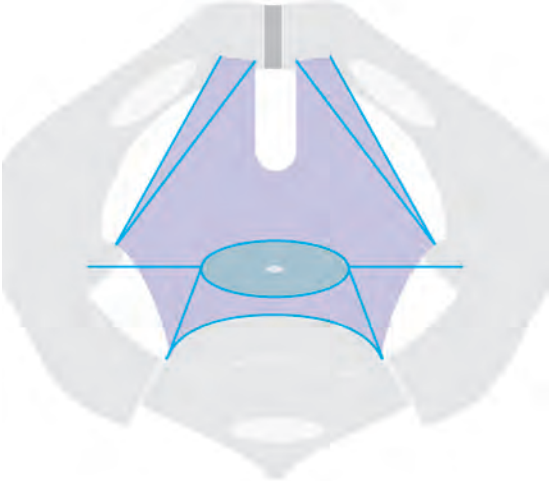

anterior longitudial median trauma

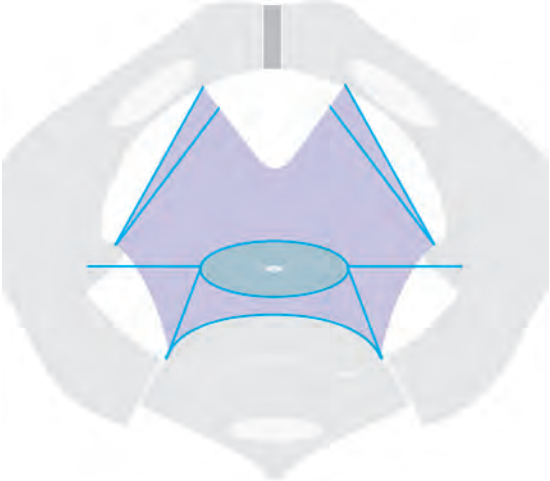

anterior trauma atf/atlam loss

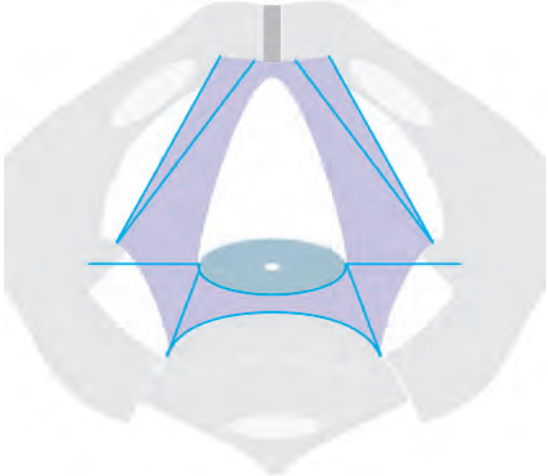

fascia trauma stress incontinence

trauma endopelvic diaphragm

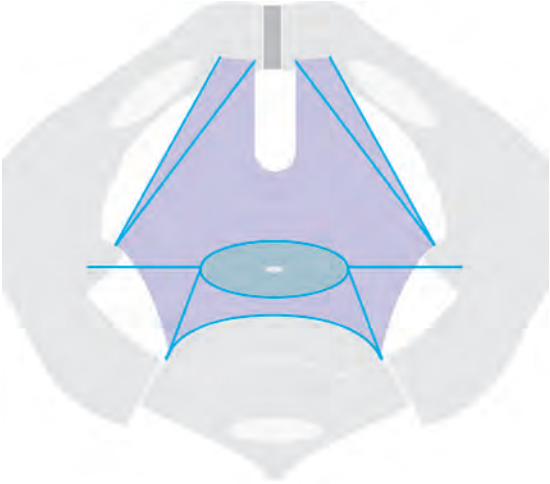

anterior longitudial median trauma

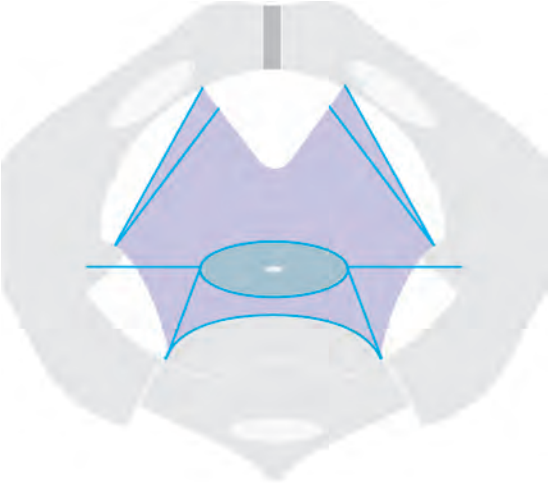

anterior trauma atf/atlam loss

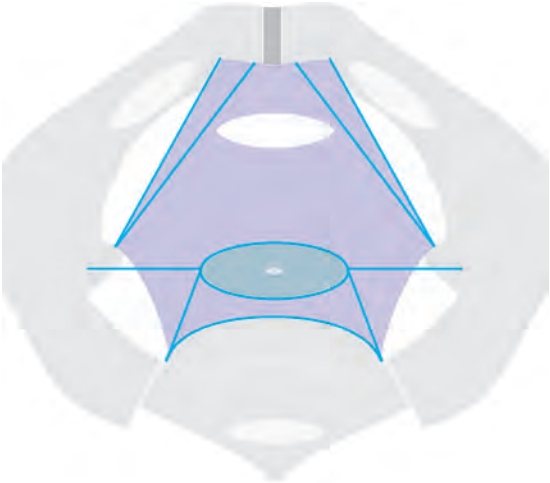

transverse trauma

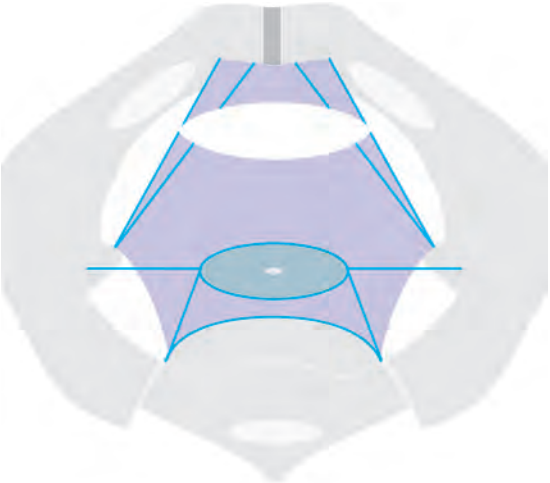

transverse trauma
atf/atlam loss

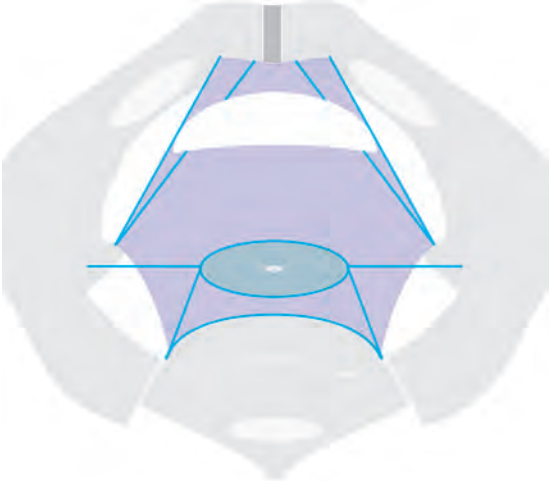

quartercircular trauma

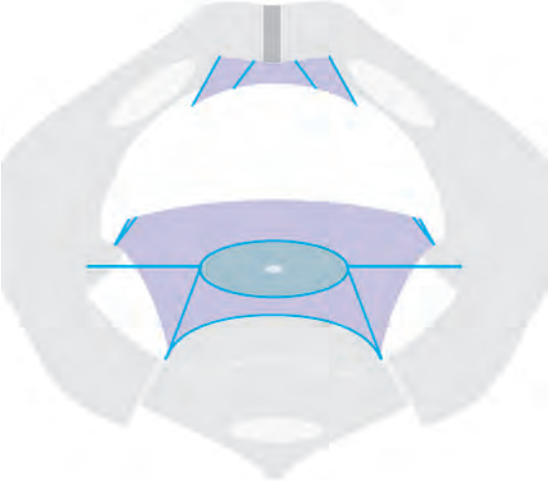

semicircular trauma

trauma endopelvic diaphragm

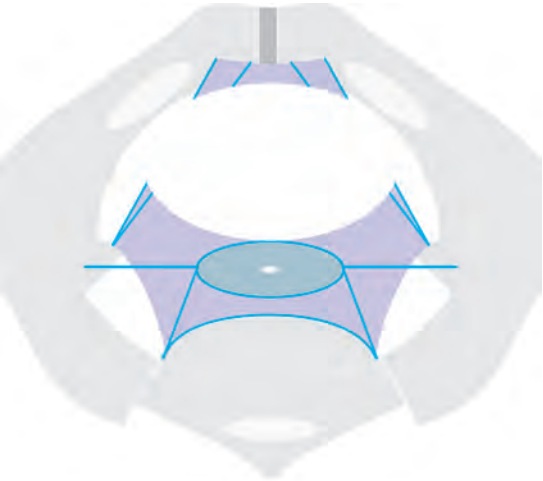

subtotal fascia loss

subtotal diaphragm loss

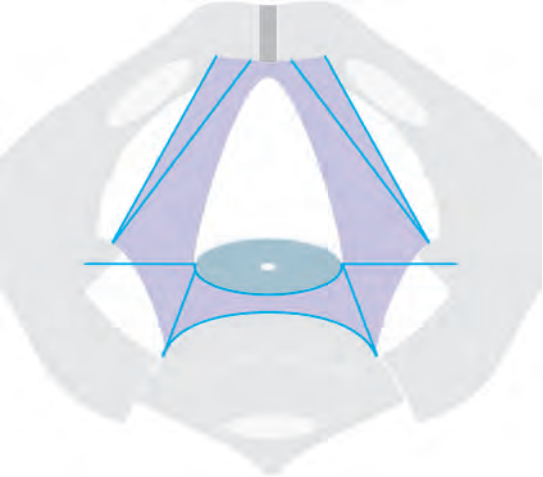

fascia trauma stress incontinence

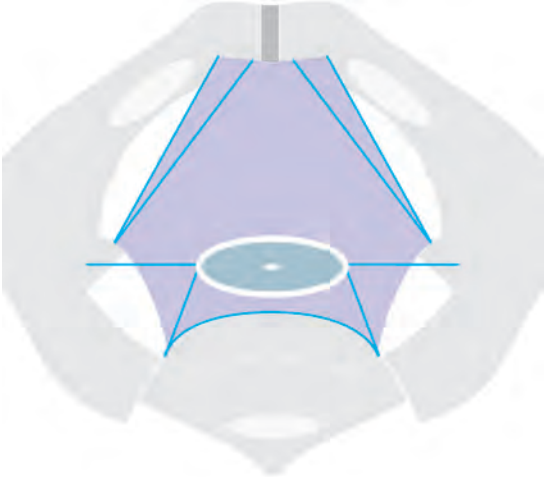

detachment cervix anchoring

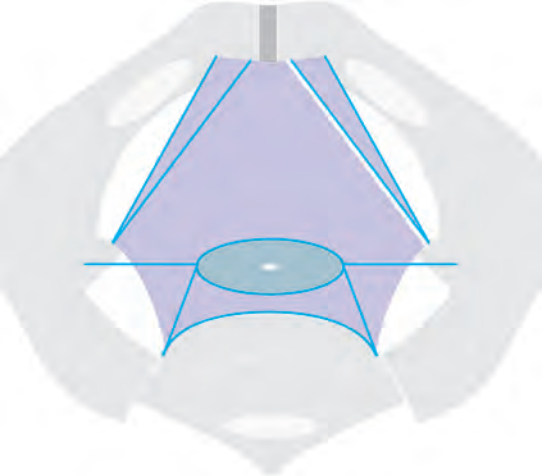

shearing at atf

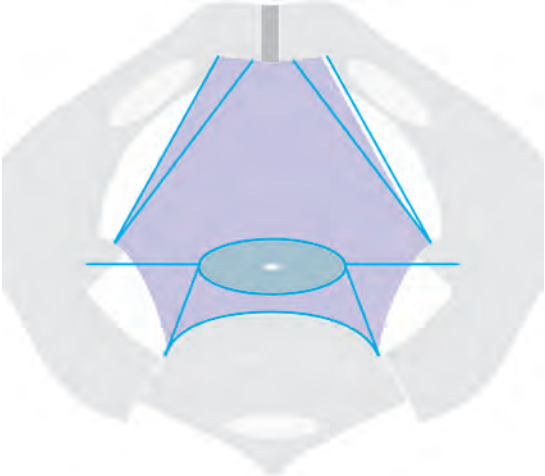

shearing at atlam

trauma endopelvic diaphragm

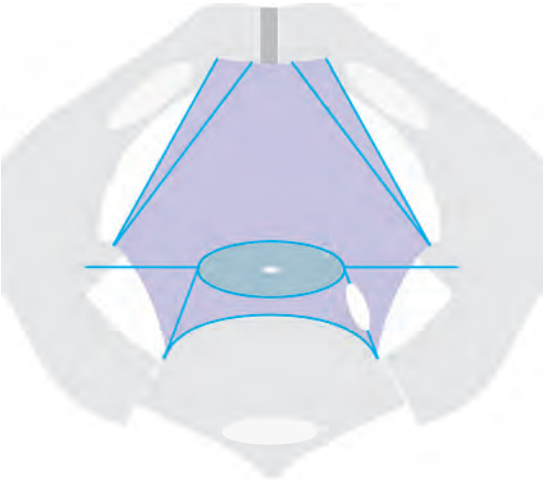

trauma sacrouterine ligament

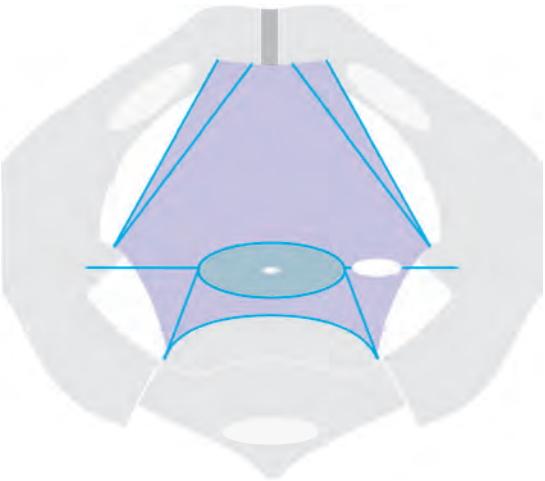

trauma cardinal ligament

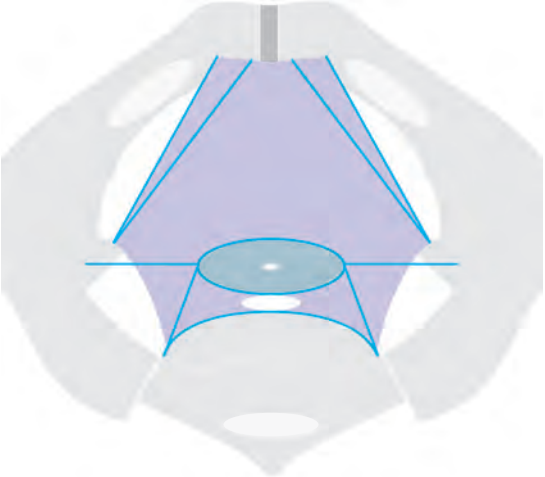

fascia defect enterocele

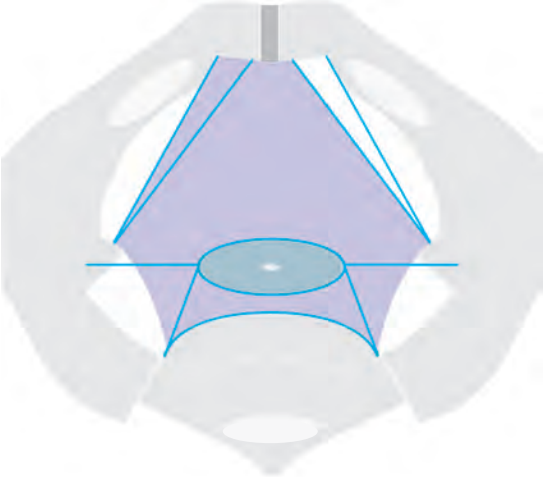

total fascia sheath loss

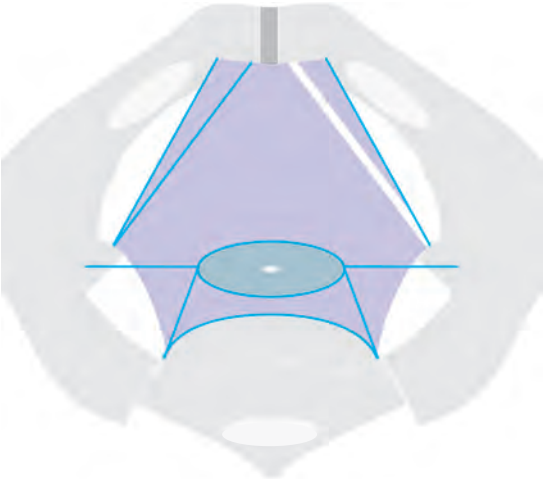

total atf loss

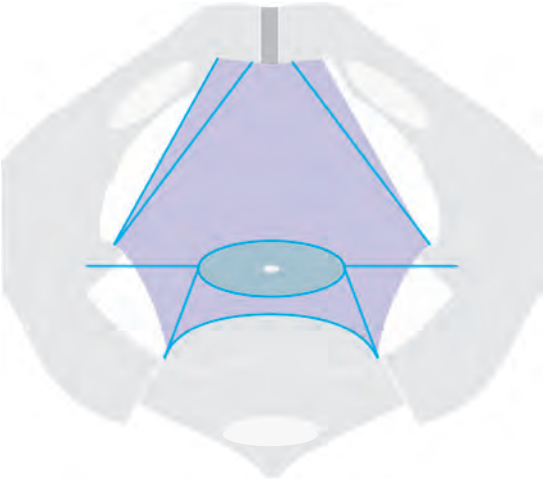

total atlam loss

basic science

pelvis anatomy

functional pelvis anatomy

anatomy of female pelvis

based on existing anatomic textbooks

introduction

mastering the pelvis anatomy is not an easy task since the anatomy is complicated but it is the first step for any surgeon in whatever field since reconstruction of the functional anatomy will ensure normal physiology

here only a short comprehensive outline is given as a start/incentive to more extensive self-study; it is based on existing anatomic textbooks with some personal comments

only the lesser or true pelvis is considered within the context of the abdominopelvic cavity

bony pelvis

consists of 3 paired bones and 2 single bones connected to each other via joints and ligaments
paired **pubis** bones
    with body and superior/inferior rami as joined anteriorly in the midline by the **symphysis pubis**
paired **ischium** bones
paired **ilium** bones
single **sacrum** bone
single **coccyx** bone
the 3 paired bones pubis, ilium and ischium are fused together by ossification

it forms a cavity for the distal outlet end organs of the urinary tract, the genital tract and the digestive tract; normally in a continent way

it is also part of the musculoskeletal locomotion system with insertions for abdominal muscles and hip muscles

ligaments stabilizing bony pelvis

symphysis cartilage
joining pubis bones anteriorly in the median; whilst whole complex also referred to as symphysis

arcuate ligament
between inferior pubis bones just caudad from symphysis cartilage

sacroiliac ligaments, dorsal and ventral
between ilium bones and sacrum

sacrotuberous ligaments
broad base from dorsal posterior ilium spine, dorsal lateral parts of sacrum, upper lateral part of coccyx to medial ischium tuberosity

sacrospinous ligaments
in front of sacrotuberous ligaments, triangular in shape with a broad base from lateral lower parts of sacrum, lateral upper part of coccyx to ischium spine; (ischio)coccygeus muscles fused with its lower pelvic aspects

pelvis divided into greater pelvis and lesser or true pelvis

for anatomic and functional reasons the pelvis is divided into a greater and a lesser or true pelvis as divided by the linea terminalis which also forms the inlet opening into the true pelvis

greater pelvis

consists of bones anteriorly, posteriorly and bilaterally and abdominal muscles anteriorly and forms the lower part of the abdominal cavity and is separated by the linea terminalis from the lesser or true pelvis, the topic of this book

though normally occupied by the intraperitoneal organs, also intrapelvic organs may protrude into it

true pelvis

consists of a combination of bones, ligaments and muscles lining the bones or filling up the gaps in between bones with a funnel-like shape which is short and straight anteriorly (symphysis) and longer and concave-curved posteriorly (sacrum promontory to tip of coccyx bone)

though normally occupied by the intrapelvic organs, also some intraperitoneal organs like small bowel and sigmoid colon may protrude into it

there is a pelvis inlet into the true pelvis and a pelvis outlet and several other bilateral openings like obturator foramen and (greater and lesser) sciatic foramina

functional pelvis cavity

the functional pelvis cavity is the space in between the **parietal pelvis fascia** and the **parietal peritoneum** connected to each other by the **tela urogenitalis** into which the pelvis organs with their arterial blood supply, venous drainage, lymphatic drainage and innervation are embedded; see next chapter

pelvis inlet = apertura pelvis superior

round or oval shape as the upper (bony) ring in one plane through anteriorly superior symphysis edge, laterally upper edge of superior pubis bones and linea arcuata and posteriorly the promontory; the bony ring is interrupted anteriorly by the symphysis cartilage joint and posterobilaterally by the sacroiliac joints

inclination 55-60° with horizontal from superior symphysis edge anteriorly to promontory posteriorly in the upright position

pelvis outlet = apertura pelvis inferior surface some 75-80 sq cm

diamond shape from inferior symphysis edge along ischiopubic rami to bilateral ischium tuberosities to tip of coccyx bone; the anterior triangle for the urogenital tract between symphysis and tuberosities in one plane and the posterior triangle for the digestive tract between tuberosities, sacrotuberous ligaments and tip of coccyx in another one plane

however there still remain some bony gaps posterobilaterally which are filled up by the coccygeus muscles, sacrospinous and sacrotuberous ligaments and piriformis muscles

anterior triangle in one plane with -10 to -15° inclination as to horizontal from symphysis to ischium tuberosities in the upright position

posterior triangle in one plane with 65 to 70° inclination as to horizontal from ischium tuberosities to tip of coccyx in the upright position

the direct inclination between inferior symphysis and tip of coccyx is 10-15°

anteroposterior diameter recta from inferior symphysis to tip of coccyx is 9-9.5 cm; can enlarge to 11 cm during childbirth; with transverse intertuberosity diameter of 10-11 cm

pelvis floor = part of the abdominopelvic wall

the pelvis outlet is more or less closed off by the pelvis floor structures; however with 3 openings for urethra, vagina and rectum; and consists of

levator ani muscles gap between puborectalis ledges some 25-30 sq cm
the <u>superior</u> layer of the pelvis floor; as formed by puborectalis (as sling around the anorectum), pubococcygeus and obturatococcygeus muscles and in total like a shallow bowl with its deepest point at the anus
with an anterior sagittal median hernia-prone opening of 7-8 x 3.5-4 cm (some 25-30 sq cm) between the two levator ani ledges

perineum outlet diaphragm
the <u>inferior</u> layer of the pelvis floor with perineal body as its center; formed by perineal membrane, perineal body, transversus perinei muscles, bulbospongiosus muscles, ischiocavernosus muscles, crura of clitoris, anococcygeal ligament/levator plate, coccygeus muscles, sacrospinous ligament and sacrotuberous ligament

the outgoing distal end organs of the urinary tract, genital tract and digestive tract with their continence mechanisms are firmly anchored into the pierced thru punched out openings in the perineum outlet diaphragm and constitute part of it

so the pelvis floor belongs to the abdominopelvic wall into which the outlet organs with their continence mechanism are anchored; nothing more and nothing less

inclination of 10-15° as to horizontal from inferior symphysis edge anteriorly to tip of coccyx posteriorly; in the upright position

the pelvis floor is covered on the outside by the pudendal organs: **clitoris, vestibule** and **labia minora/majora**

pelvis foramina

obturator foramen
between superior pubis, inferior pubis and ischium bones; it is closed by the obturator membrane with a small opening as a canal for blood and nerve supply to the obturator externus muscle

the sacrospinous ligament divides the space between the ischium notch/spine and sacrum/coccyx into foramina with the sacrotuberous ligament as boundary:

greater sciatic foramen
thru which piriformis muscle, superior and inferior gluteal vessels and nerves, internal pudendal vessels, pudendal nerve and sciatic nerve caudad from piriformis muscle, posterior femoral nerve and nerves to obturator and quadratus femoris muscles; is the cephalad = superior foramen

lesser sciatic foramen
thru which obturator internus muscle tendon, nerve to internal obturator muscle, internal pudendal vessels and pudendal nerve; is the caudad = inferior foramen

pelvis muscles

there are 2 intrapelvic muscles which function as exo-rotators/abductors of the hip

obturator internus muscle
originates from pelvic surface of obturator membrane and pubic and ischial margins of obturator foramen with its tendon thru the lesser sciatic foramen and inserts into medial surface of trochanter major

piriformis muscle
originates from pelvic surface of sacrum and ilium, passes thru greater sciatic foramen and inserts into upper border of trochanter major

and four extrapelvic muscles as exo-rotators of the hip: obturator externus muscle, gemellus superior muscle, gemellus inferior muscle and quadratus femoris muscle

then there are muscles which constitute the “anterior” and bilateroposterior part of the superior layer of pelvis floor as shallow bowl with anus as most caudad point

levator ani muscles
originating from pubis bone body and atlam and inserting into levator plate, coccyx and anococcygeal ligament; actually one flat muscle but normally divided into different parts

pubococcygeus muscles
from pubis bone body and atlam to levator plate and anococcygeal ligament

puborectalis muscles
medial part of pubococcygeus muscles fusing behind rectum and pulling it anteriorly

obturatococcygeus muscles
from atlam/obturator internus fascia to levator plate, coccyx and anococcygeal ligament

and **(ischio)coccygeus muscles**
from ischium spine and inferior edge of sacrospinous ligament to sacrum and coccyx

and muscles which form the anterior part of the perineum outlet diaphragm as the inferior layer of pelvis floor

compressor urethrae muscle
in the deep perineal space between perineal membrane and levator ani muscles but not mentioned in older textbooks

urethrovaginalis muscle
in the deep perineal space between perineal membrane and levator ani muscles but not mentioned in older textbooks

bulbospongiosus muscles
in the superficial perineal space from symphysis and clitoris and radiating into perineal body; closes the vagina introitus and stabilizes the (anterior) anus

ischiocavernosus muscles
in the superficial perineal space from ischium tuberosity into clitoris

transversus perinei muscles
from ischium tuberosity and radiating into perineal body for stabilization of anterior anus

pelvis connective tissue corpus intrapelvinum

the organs of the pelvis together with their arterial blood supply, venous drainage, lymphatic drainage and innervation are embedded into and suspended/connected to the pelvis wall and to each other via a complicated system of connective tissue, called connective tissue body of pelvis = corpus intrapelvinum; see special chapter

it consists of a cohesive mixture of collagen for strength, elastin for passive elasticity and plasticity and smooth muscle tissue for active tonus and relaxation; under control of intrinsic myogenic impulses via baro- and stretch receptors as modulated by extrinsic impulses from the autonomic nervous system and from hormones

in a loose, dense or condensed form and may be highly specialized according to the needs as fascia, ligament or plica such as

parietal pelvis fascia
the general layer that lines the inner aspects of the pelvis cavity wall/floor; together with the periost

visceral fascia
from tela urogenitalis for packing/encapsulating the organs as fascia of the organs and for ensheathing the blood vessels, lymphatic vessels and nerves

obturator membrane
the obturator membrane closes the obturator foramen and forms the origin of the obturator externus muscle on the outside and the origin of the obturator internus muscle on the inside

obturator fascia
fascia covering obturator internus muscle; from/into which atf and atlam originate/insert

arcus tendineus of levator ani muscle = atlam
as line of fusion from 1.5-2 cm laterally from midline from posterior pubis bone body over obturator internus muscle fascia to ischium spine; as origin of levator ani muscle

levator ani fascia
fascia covering levator ani muscle

arcus tendineus fasciae = atf
as line of fusion bilaterally from posterior pubis bone body 0.5-1 cm from midline pubis symphysis to ischium spine; as anterolateral attachment of endopelvic diaphragm to pelvis wall
it is connected to the obturator fascia and to the arcus tendineus of levator ani muscle via a narrow triangular fascia sheath
inclination of 25-30° as to horizontal from anterior to posterior in upright position

pubocervical musculofascia = vesicovaginal musculofascia
in between the posterior bladder wall and anterior vagina wall as the anterior part of the endopelvic diaphragm; see special chapter

arcus tendineus of rectovaginal fascia = atrf
as line of fusion from the lateral side of perineal body over levator ani fascia to ischium spine and fuses with the posterior part of the arcus tendineus fasciae

rectovaginal fascia = prerectal fascia
in between the posterior vagina wall and anterior rectum wall and fixed anteriorly to the perineal body, (bi)laterally to arcus tendineus of the rectovaginal fascia and posteriorly to the cervix and the sacrouterine ligaments

vesicoumbilical fascia
in between bilateral vesicoumbilical ligaments from bladder to umbilicus

perineum membrane
semicircular from symphysis and arcuate ligament in between both ischiopubic rami of pubis bones up (in)to perineal body and transversus perinei muscles with small opening for the urethra and wide opening for the vagina
this membrane separates the deep perineal space, between the membrane and levator ani muscle fascia, from the superficial perineal space, between the membrane and the subcutaneous fascia

perineal body = centrum tendineum perinei
wedge-like smooth muscle/connective tissue structure in between the vagina and the anus; into which the perineum membrane, bulbospongiosus muscles and transversus perinei muscles radiate; as centrum tendineum perinei
it stabilizes the (anterior) anus in its anatomic position since it is firmly attached to the external sphincter ani muscle

medial vesicoumbilical ligament
obliterated urachus
from median bladder to umbilicus
restricting the upward movement of the bladder

(bi)lateral vesicoumbilical ligaments
obliterated umbilical arteries
from (bi)lateral internal iliac artery to umbilicus
restricting the upward and sideward movement of the bladder

pubovesical ligaments = pubovesical muscles
condensation of pubocervical musculofascia as attachment to pubis bone
stabilizing the posterior bladder neck

posterior pubourethral ligaments = pubourethral muscles
condensation of pubocervical musculofascia as attachment to pubis bone body
stabilizing the posterior proximal/mid urethra wall

anterior and intermediate pubourethral ligaments
condensation of perineum outlet diaphragm
anchoring distal urethra and external urethra opening

broad ligament = parametrium from lateral uterus to pelvis wall comprising

round ligament (muscle)
smooth muscle structure from anterolateral uterus horn thru inguinal canal and radiating into labium majus and mons pubis
stabilizing uterus in anteflexion/version

infundibulopelvic ligaments = suspensory ligament of ovary
from ovary to pelvis wall
suspends ovary

ligamentum ovarii proprium = proper ovary ligament
from ovary to lateral uterus
connects ovary to uterus

cardinal ligaments
from ilium/ischium bones to (bi)lateral cervix in a frontal plane cephalad to the ischium spines
suspending/connecting the cervix and endopelvic diaphragm bilaterally to the pelvis wall

sacrouterine ligaments = rectouterinus muscles
from cervix to rectum and sacrum
attached to (ischio)coccygeus fascia and piriformis fascia via fascia sheath

pelvis organs

the organs with their arterial blood supply, venous drainage, lymphatic drainage and innervation are embedded into and connected to the pelvis wall and each other by the corpus intrapelvinum as part of the tela urogenitalis
in contrast with the intraperitoneal organs which have a single posterior vascular supply and innervation, the pelvis organs have a bilateral vascular supply and innervation whilst the rectum has even a single dorsal combined with bilateral vascular supply and innervation

ureter
though the ureter is completely embedded into the tela urogenitalis it can be divided into a proximal retroperitoneal abdominal part and a distal subperitoneal pelvic part
suspended/connected to lateral pelvis wall by parametrium and paracystium as part of tela urogenitalis
blood supply
small vessels from all arteries it crosses
innervation
by autonomic nervous system

bladder = vesica = cystis
suspended/connected anteriorly onto the abdominal wall by the medial and lateral vesi coumbilical ligaments and to the symphysis by loose connective tissue and thin fluid film and by the pubovesical ligaments and to the lateral pelvis wall by the paracystium; all as part of the tela urogenitalis
blood supply
upper part: usually by 2 or 3 superior vesical arteries from upper part of umbilical artery
lower part/neck: by inferior vesical artery and neck also by vaginal arteries
innervation
many nerve fibers from vesical (and prostatic) plexus as forward extension of inferior hypogastric plexuses from autonomic nervous system

female urethra
suspended/connected to the symphysis by loose connective tissue and thin fluid film and by the pubourethral ligaments as part of the endopelvic diaphragm and distally anchored into perineum outlet diaphragm
blood supply
upper part: inferior vesical artery
middle part: inferior vesical artery and uterine artery
lower part: internal pudendal artery
innervation
upper part: vesical and uterovaginal plexuses of autonomic nervous system
lower part: pudendal nerve

uterus = metra, tubes and ovaries
though they are situated intraperitoneally they belong to the pelvis organs
they are suspended/connected to the lateral pelvis wall by the parametrium as part of the tela urogenitalis
blood supply
uterine artery
innervation
autonomic sympathetic and parasympathetic system

cervix = centrum tendineum intrapelvinum
entering thru the apical endopelvic diaphragm and proximal anterior vagina wall; and stabilized in its anatomic position by the endopelvic diaphragm and cardinal ligaments; it is also the centrum tendineum intrapelvinum
blood supply
branches of uterine artery
innervation
autonomic sympathetic and parasympathetic system

vagina = colpos
suspended/connected to the (bi)lateral pelvis walls by the paracolpium as part of the tela urogenitalis and distally anchored into perineum outlet diaphragm
the anterior vagina wall is loosely adherent to pubocervical musculofascia/endopelvic diaphragm and as such indirectly fixed to the pelvis wall
the posterior vagina wall is adherent to prerectal fascia and perineal body and as such indirectly fixed to the pelvis wall
blood supply
upper part: branches of uterine artery
vaginal artery as 2 or 3 branches from internal iliac artery may anastomose in median plane to form longitudinal trunks as anterior and posterior azygos arteries of vagina
lower part: branches from artery of bulb of vestibule
innervation
by uterovaginal plexus of autonomic nevous system except for
its lowermost part by pudendal nerve
therefore there is little sensitivity except for its lowermost part

rectum = proctos
is adherent to the sacrum and rests upon the levator ani plate, anococcygeal ligament, and coccyx and connected (bi)laterally to the pelvis wall by the paraproctium as part of the tela urogenitalis
reflection of peritoneum at anterior rectum at 5-6 cm from anus; distal part of rectum not covered by peritoneum
blood supply
most important unpaired superior rectal artery as continuation of inferior mesenteric artery
then paired middle rectal artery, inferior rectal artery and median sacral artery
extensive anastomosis between the arteries; so if inferior mesenteric artery ligated, the middle and inferior rectal artery can supply the entire rectum
innervation
autonomous sympathetic and parasympathetic system: from pelvic plexus and from mesenteric plexus; and enteric nervous system

anorectum with sphincter ani complex
the anorectum is fixed in its position by anococcygeal ligament, levator plate, pubococ cygeus muscles, puborectalis muscles, perineal body (centrum tendineum perinei), bulbospongiosus muscles and transversus perinei muscles; and it is anchored into the perineum outlet diaphragm
blood supply
unpaired superior hemorrhoidal artery = superior rectal artery (from inferior mesenteric artery) and paired middle hemorrhoidal artery = middle rectal artery and paired inferior hemorrhoidal artery = inferior rectal artery (both from internal pudendal artery)

innervation
inferior rectal nerve from pudendal nerve also for external sphincter whilst the internal sphincter is under autonomic (sympathetic, parasympathetic and enteric) nervous system control

pudendal organs

introitus or vulva or vestibule

labia majora/minora
blood supply
anterior labial branches from external pudendal artery and posterior labial branches from internal pudendal artery
innervation
anterior labial nerve (ilioinguinal nerve) and posterior labial nerve from pudendal nerve

clitoris
blood supply
clitoridal artery from internal pudendal artery
innervation
pudendal nerve and ilioinguinal nerve

pelvis blood supply

internal iliac (hypogastric) artery
from common iliac artery
supplies most of the pelvis

internal pudendal artery
from internal iliac artery
inferior rectal artery
posterior scrotal (labial) branches
perineal artery
artery of penis bulb
artery of bulb of vestibule
urethral artery
deep artery of penis or clitoris
dorsal artery of penis or clitoris

visceral branches from internal iliac artery
umbilical artery
superior vesical artery
ductus deferens artery homologous to uterine artery
inferior vesical artery

uterine artery
from internal iliac artery

vaginal artery
from internal iliac artery; sometimes in combination with uterine artery

superior rectal artery; unpaired
as continuation of **inferior mesenteric artery**: most important

middle rectal artery
either directly from internal iliac artery or from beginning of pudendal artery
with collaterals to

inferior rectal artery
from internal pudendal artery

pelvis nerves

nerve supply = innervation
from the sacral and coccygeal spinal nerves and from the pelvic part of the autonomic nervous system from sympathetic trunk and aortic plexus; and from the enteric nervous system
sacral plexus (L4 to S5)
12 named branches:
7 distributed to the buttock and lower limb:
superior gluteal nerve (L5 to S1)
inferior gluteal nerve (L5 to S2)
nerve to quadratus femoris muscle (L4 to S1)
nerve to obturator internus muscle (L5 to S2)
posterior femoral cutaneous nerve (S1 to S3)
perforating cutaneous (inferior medial clunial) nerve (S2, S3)
sciatic nerve (L4 to S3), largest nerve in the body, leaves pelvis thru greater sciatic foramen below the pririformis muscle; the two parts may leave separately, peroneal portion pierces the piriformis or even above piriformis and the tibial portion passes below it and the two parts remain separate throughout their course
5 distributed to the pelvis
nerve to piriformis muscle (S1, S2)
nerves to levator ani and coccygeus muscle (S3, S4)
nerve to externus sphincter ani muscle (perineal branch of S4)
pelvic splanchnic nerves (S (2), 3, 4, (5))
and
pudendal nerve (S2, 3, 4)
exits pelvis thru greater sciatic foramen below piriformis muscle, crosses the back of the ischium spine, re-enters pelvis thru lesser sciatic foramen into ischiorectal fossa, gives of inferior rectal nerve for sphincter ani externus muscle and skin around anus and anus mucosa up to pectinate line, enters/exits pudendal canal and gives of perineal nerve for the perineum outlet diaphragm and ends as dorsal penis/clitoris nerve

some important facts

upright position
the anterior superior iliac spines and pubis bone tubercles are in the same frontal plane in the upright position

the promontory, ischium spines, cervix, ischium tuberosities and perineal body are in the same frontal plane in the upright position

axis symphysis pubis
30-45° as to horizontal/ground from caudad=inferior to cephalad=superior in upright position; 5-6 cm broad

axis endopelvic diaphragm/pubocervical musculofascia
25-30° as to horizontal/ground from symphysis to sacrum in upright position

angle between arcus tendineus fasciae and symphysis
this is in the range of 110-125°

discussion

though this is a condensate from the existing textbooks the author added some things and phrased some things in a different way

the author uses the term obturatococcygeus muscle instead of iliococcygeus muscle since the muscle originates from/inserts into the obturator internus fascia via the atlam and **not** from/into the ilium bone in human beings; though in animals it does

first edition august 2007

last edition october 2018

pelvis

pelvis

symphysis pubis

arcuate ligament

sacroiliac ligaments

stabilizing pelvis ligaments

sacrospinous ligament

sacrotuberous ligament

sacrotuberous ligament
sacrospinous ligament
obturator foramen

greater sciatic foramen

lesser sciatic foramen

pelvis foramina

arcus tendineus levator ani muscle
atlam

arcus tendineus fasciae
atf

atf + atlam

origin pubococcygeus muscle
as part of levator ani

origin obturatococcygeus muscle
as part of levator ani

origin coccygeus muscle

origin obturator internus muscle

origin obturator internus muscle

origin piriformis muscle

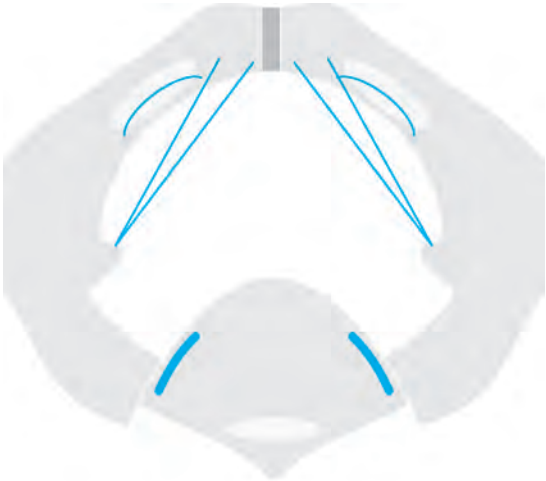

origin piriformis muscle

cervix

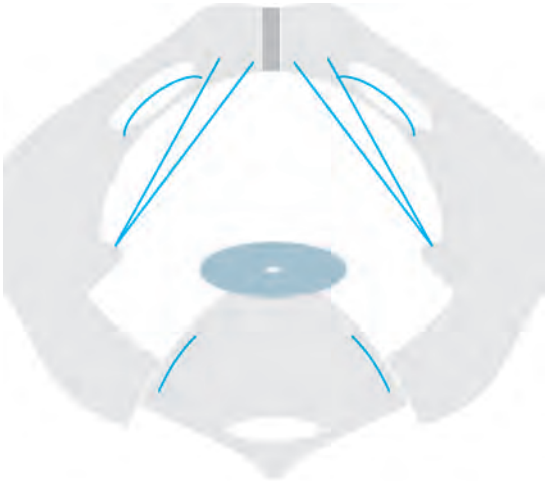

cervix

cardinal ligaments

cervix + cardinal ligaments

sacrouterine ligaments

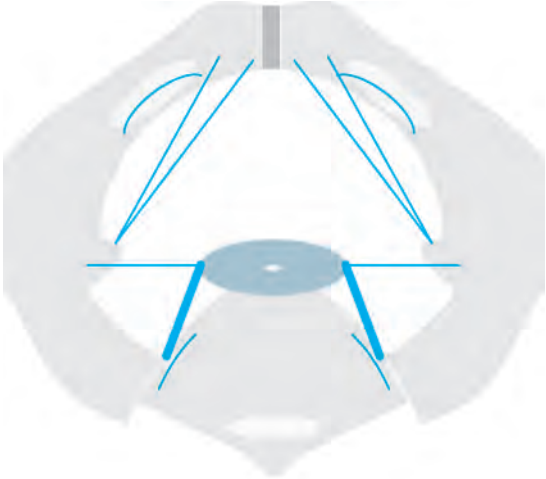

cervix + sul

sacrotuberous ligaments

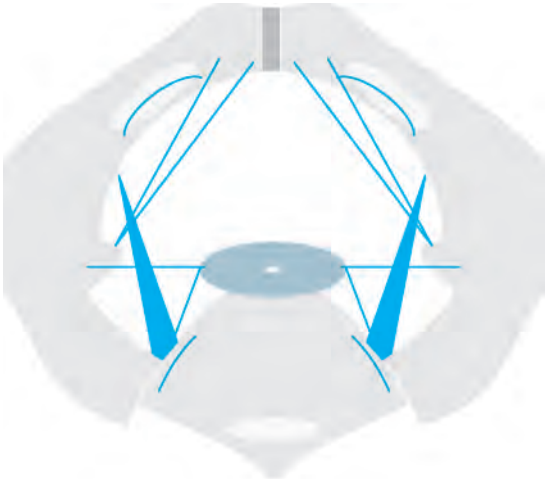

sacrotuberous ligaments

sacrospinous ligaments

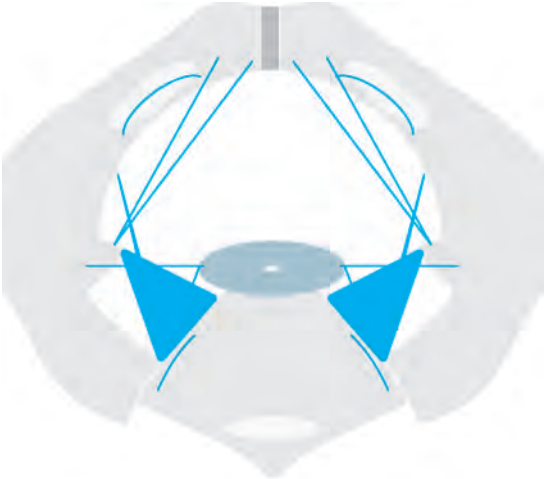

sacrospinous ligaments

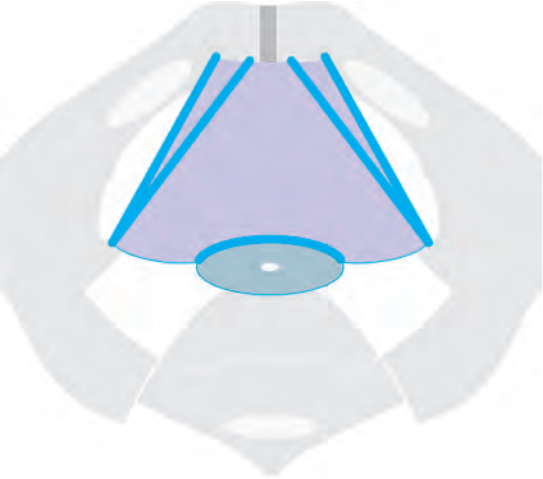

pubocervical musculofascia

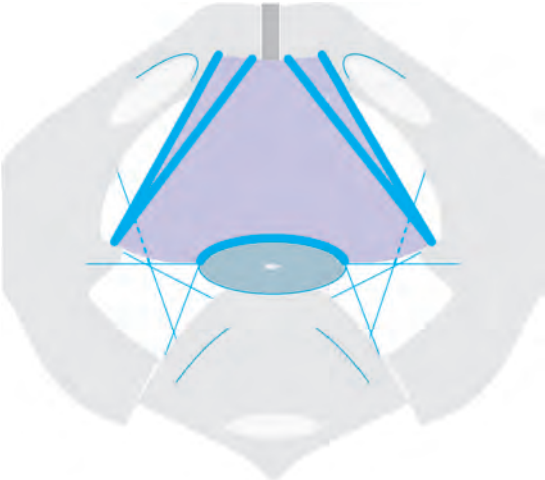

pubocervical musculofascia

rectovaginal fascia

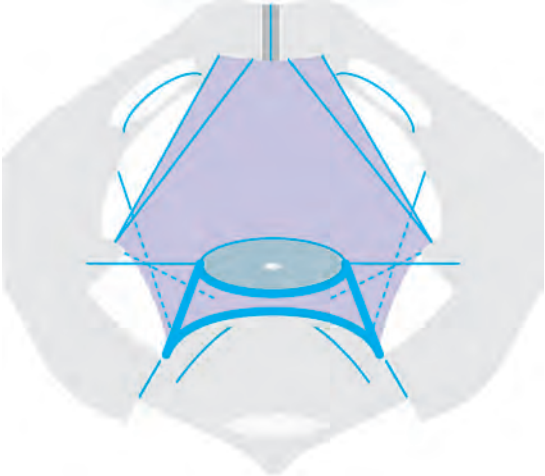

rectovaginal fascia

functional anatomy of female pelvis

surgical interpretation

introduction

the functional anatomy of the pelvis structures is a highly complicated interaction of the different pelvis organs as the distal outlet end parts of the urinary tract, the genital tract and the digestive tract; normally in a continent way

the different organs with their arterial blood supply, venous drainage, lymphatic drain age and innervation are embedded into and protected by and encapsulated and/or ensheathed by a complex connective tissue body as corpus intrapelvinum as part of the tela urogenitalis

the most difficult part to understand is the function of the corpus intrapelvinum which consists of a cohesive mixture of collagen, elastin and smooth muscle tissue in a loose, dense or condensed form depending upon the function needed under physiologic and pathologic stress

collagen for strength, elastin for passive elasticity and plasticity and smooth muscle for active tonus and relaxation all under autonomic innervation; see next chapter

however, how hard the author studied he failed to comprehend the various theories since there was a discrepancy between what he found during his extensive obstetric trauma reconstructive surgery and all these theories

the human anatomy does not change, except for under evolutionary impulses; but it seems another concept is needed for a comprehensive understanding

though it is based on existing anatomic textbooks, the following constitutes a personal interpretation by the author as a reconstructive surgeon

function

this whole complex must take care of and is responsible for a more or less independent (and if needed combined) simultaneous functioning of the different organs and tracts from each other like

rapid filling/storage of urine with rapid increase in bladder size and

urine continence until

voluntary micturition with instantaneous decrease in bladder size

rapid filling/storage of liquid_solid stools/gas with rapid increase in rectum size and

stool/flatus continence until

voluntary defecation with instantaneous decrease in rectum size

sexual intercourse with rapid increase/decrease in vagina size and shearing

excretion of menstruation fluid

coping with hormonal changes and ageing changes during the various periods of life

slow increase in uterus size during pregnancy till enormous proportion and

pregnancy continence and

coping with hormonal flooding during pregnancy as slow preparation for

:

childbirth with enormous widening/opening of cervix, vagina and outlet diaphragm

remodeling after childbirth during the involution phase of the puerperium

withstand intraabdominopelvic hydrostatic (especially pregnancy) pressure and

intraabdominopelvic compression pressure

stabilizing/securing the different organs in their variable anatomic position

under all possible body positions and

under all normal filling stages

prevention of urogenital prolapse

prevention of prolapse of intraperitoneal contents and distal digestive tract

functional pelvis anatomy

the abdominopelvic space can be considered as a confined space with hydrostatic and compression pressure

the abdominopelvic cavity can be divided into **three** functional spaces:

the **intraperitoneal space** for the digestive tract enclosed by the parietal peritoneum

the **retroperitoneal space** for large vessels, pancreas, kidneys etc enclosed by parietal peritoneum anteriorly and spine with trunk muscles posteriorly

in open contact caudally with

the **subperitoneal space of pelvis** for the distal outlet organs of the urinary tract and the digestive tract and for the whole genital tract

true pelvis space

true pelvis cavity
a confined space for the distal outlet organs of the urinary tract anteriorly, the genital tract in the middle and the digestive tract posteriorly with hydrostatic and compression pressure; normally in a continent way and

enclosed by
parietal pelvis fascia covering pelvis wall/floor muscles
and
parietal peritoneum as boundary of intraperitoneal cavity
as connected to each other by
tela urogenitalis/subserosa with corpus intrapelvinum and endopelvic diaphragm

divided into
anterior pre_subperitoneal compartment
for the distal end parts of the urinary tract: pelvic ureters, bladder and urethra
median subperitoneal compartment
for the (also distal end parts of) genital tract: uterus, adnexa, cervix and vagina
posterior retro_subperitoneal compartment
for the distal end parts of the digestive tract: rectum, anorectum and sphincter ani

pelvis organs

in contrast with the intraperitoneal organs which have a single dorsal vascular supply and innervation, the pelvis organs have a bilateral blood supply and innervation whilst the rectum has a single dorsal blood supply and innervation combined with a bilateral blood supply and innervation
these organs belong to the pelvis cavity contents, are embedded into the connective tissue body of pelvis and do not belong to the pelvis floor which is just the pelvis wall and as such should not be addressed as being the same

corpus intrapelvinum as 3-dimensional dynamic matrix

connective tissue organ of pelvis consists of a cohesive mixture of collagen for strength, elastin for passive elasticity and plasticity and mostly smooth muscle fibers for dynamic active non-fatigue tonus in a loose, dense or condensed form as
a dynamic matrix into which the organs and their supply are embedded and suspended/ connected to the pelvis wall and each other by highly specialized structures
protecting the organs and their supply against trauma and stabilizing/securing them in their variable anatomic position
as coordinated by intrinsic myogenic impulses via baro- and stretch receptors and by extrinsic impulses from the autonomic (sympathetic, parasympathetic and probably also ?enteric?) nervous system and from other neurotransmitters and from hormones
considered to be a **fluidum** since no sharp demarcation between the archaic matrix and its specialized structures

endopelvic diaphragm

highly specialized structure of corpus intrapelvinum from pubis bone bodies anteriorly to sacrum posteriorly as connected to its bilateral arcus tendineus fasciae with **cervix as centrum tendineum intrapelvinum** since all musculofascia structures are connected firmly to it and it is anchored within the endopelvic diaphragm
as first line of counteracting intraabdominal hydrostatic pressure and
supporting the pelvis organs with their supply and continence mechanisms in their anatomic position and
preventing herniation of the distal urinary tract, genital tract, intraperitoneal contents and distal digestive tract into the zero-pressure vagina

defects within the endopelvic diaphragm are responsible for incontinence and pelvis organ prolapse

pelvis floor as one functional unit as part of abdominopelvic wall

superior upper layer
levator ani muscles as “pelvis diaphragm”; on its own this cannot be considered as a real diaphragm since there is a large anterior median gap of 7-8 x3.5-4 cm; this means that out of the total of 75-80 sq cm of the pelvis outlet some 25-30 sq cm are missing or roughly one third
however, they are important since the vagina and rectum are indirectly connected to its fascia; as suspension/connection to the pelvis wall
they play a direct role in the stool continence mechanism to which they are anatomically connected and
only an indirect role in the urine continence mechanism to which they are not connected anatomically
they support the perineum outlet diaphragm since there is a firm connection between the two in the region of the perineal body, anus with external sphincter ani muscle, leva tor plate, (ischio)coccygeus muscles and sacrospinous and anococcygeal ligaments
inferior lower layer
perineum outlet diaphragm into which the end outlet organs with their striated sphincter mechanisms are anchored and supporting directly and the urine and stool continence mechanisms; it includes levator plate/(ischio)coccygeus muscles
this constitutes a real diaphragm between the abdominopelvic cavity and the outside as final barrier
together with the end organs it forms part of the anatomic continence mechanisms of the urinary tract, the genital tract and the digestive tract
since the final outlet organs are firmly anchored into it, first these can only prolapse to the outside by a kind of intussusception and
second, contraction of the muscles and increase in its tonus during pelvis floor muscle exercises will contribute directly and positively to the continence mechanisms
in quadrupeds the pelvis floor into which the distal outlets organs are anchored has the function of an abdominal side wall whilst the ventral anterior abdominal wall is the floor; by becoming bipeds this was rotated 90° backwards
so the pelvis floor is part of the abdominopelvic wall, just as the anterior abdominal wall, nothing more and nothing less
defects within the pelvis floor are not the cause but the sequel of incontinence and pelvis organ prolapse

no role of **anterior vagina wall** as “hammock”

the anterior vagina wall cannot contribute to withstand intraabdominal pressure or to secure the pelvis organs in their variable anatomic position since
the whole vagina (wall + its visceral fascia) is extremely distensible and as such lacks the stiffness characteristics required; as such it also cannot support the anatomic urine continence mechanism
it is hanging onto the endopelvic diaphragm in the upright position; and as such it is “dragging” this diaphragm down and cannot support this diaphragm to support the anatomic urine continence mechanism
normally there is no intravaginal filling content and as such the vagina is a low- or zero-pressure organ
therefore the vagina cannot prolapse into the other high(er)-pressure organs or cavities whilst the other organs can easily herniate into the zero-pressure vagina once there are defects within the musculofascia structures of the endopelvic diaphragm of the corpus intrapelvinum in between these organs and the vagina
the support to the posterior urethra is not by the anterior vagina wall like a hammock with 2-point fixation which would allow rather large forward and backward swing move ments of the posterior urethra wall but
the support is by the endopelvic diaphragm with circumferential fixation like the skin of a drum or a trampoline allowing slight upward and downward movements depending upon the tonus and relaxation of the smooth muscle fibers of this diaphragm by reflex action by myogenic impulses as modulated by the autonomic nervous system

discussion

there is an enormous amount of research done mostly based on postmortem dissection and indirect imaging; however, the author failed to understand the functional anatomy as described and the resulting theories could not be confirmed by him in the living patient

the author gives a very personal interpretation of the functional anatomy as based on findings and evidence-based results during and following his extensive obstetric trauma reconstructive surgery; this does not mean he is right since it is the view of a surgeon and not of an anatomist; but definitely another concept is needed

though the author was probably one of the first already in 1987 to use and then in 1994 to describe the function of the anterior vagina wall as a hanging mat (= hammock with 2-point bilateral fixation) this is not correct since the intact endopelvic diaphragm (with overall circumferential fixation onto the pelvis walls like the skin of a drum or trampoline) is securing the posterior urethra/uv-junction/bladder neck in their anatomic position allowing only slight cephalad/caudad movement

a hammock would allow far greater mobility of the (posterior) urethra especially from anterior to posterior with traction in the longitudinal urethra axis

the notion that the levator ani muscles are of paramount importance for the female urine continence mechanism and for (the prevention of) prolapse cannot be confirmed by the author; please look at the functional anatomic configuration

there is nowhere direct contact between the midline urethra/uv-junction/bladder neck (anatomic continence mechanism) and the lateral levator ani muscles

the urethra lies anteriorly at the midline against the symphysis and the nearest point the levator ani muscles come to the urethra is bilaterally 1.5-2 cm away at the most anterior part of the arcus tendineus of levator ani muscles (atlam); then the atlam runs immediately laterally and posteriorly to the ischium spine father away from the midline and urethra; so contraction cannot have a direct effect upon the urethra

the only thing possible is that by contraction with compression of lateral/posterior vagina walls the anterior vagina wall with attached endopelvic diaphragm moves cephalad/anteriorly bringing the posterior urethra wall nearer to the anterior urethra wall with an increase in outflow resistance and stronger intrinsic closing forces

the notion that the intact levator ani muscles prevent prolapse cannot be confirmed; to the author it looks far-fetched since there is nowhere direct contact between the pelvis organs and the pelvis floor/wall muscles

consider the tube-like configuration of the pelvis space and all the different intrapelvic structures between the pelvis floor (muscle fascia) and parietal peritoneum;

by what mechanism would the action of the levator ani muscles contribute and how can the pelvis floor structures as abdominopelvic wall prevent internal prolapse of pelvis organs

pelvis organ prolapse is herniation of the high-pressure organs thru defects within the endopelvic diaphragm into the zero-pressure vagina so that the urethra, bladder, cervix, intraperitoneal contents and rectum are no longer supported and start to descend

if there is pelvis organ prolapse, these slide unopposed “over” the levator ani muscles and other pelvis floor structures thru the vagina towards the outside

this process cannot be prevented or stopped by the levator ani muscles or other pelvis floor structures, either relaxed or contracted

based upon personal clinical and surgical research in the obstetric trauma the following proved to be something the author could understand

the pubocervical musculofascia/endopelvic diaphragm is separating the high pressure organs from the zero-pressure vagina and does not belong to the pelvis floor

the pubocervical musculofascia/endopelvic diaphragm plays an important role in stabi lizing the pelvis organs in their position supporting the female continence mechanisms

transverse, quartercircular as combined with lateral, semicircular combined with lateral and longitudinal defects of the endopelvic diaphragm are found in the obstetric fistula; by repairing all these defects meticulously either first at repair or later at post repair incontinence surgery the continence was restored

median defects in the endopelvic diaphragm play an important role in the pathophysio logy of genuine intrinsic stress incontinence: lateral defects were not found since the musculofascia fibers retract bilaterally towards the atf; by meticulous repair of these defects full continence was restored in over 98% of the patients

median defects in the endopelvic diaphragm play an important role in the pathophysio logy of pelvis organ prolapse like cystocele and uterus/cervix prolapse; lateral defects are not involved since the musculofascia fibers retract bilaterally towards the atf

in both genuine incontinence and pelvis organ prolapse a predisposing factor is a wide pelvis with wide pubic arch since the span between the ischium spines is so wide that median defects within the endopelvic diaphragm may develop

the female urine and stool continence mechanisms will be presented in separate chapters

the abdominopelvic muscular wall consists of the anterior abdominal wall into which the urachus and umbilical cord are anchored as umbilicus and of the pelvis floor into which the outlet organs of the urinary, genital and digestive tract are anchored

in quadruped animals the anterior abdominal wall is the floor and the pelvis floor the posterior abdominopelvic wall; then by becoming bipeds this configuration rotated 90° backwards whereby the posterior abdominopelvic wall became the pelvis floor

levator ani muscles

the levator ani muscle is one muscle originating from/inserting into pubis bone and obturator muscle fascia inserting into/originating from coccyx, levator plate/anococcy geal ligament and deep sphincter ani muscle

in reading the textbooks and articles it is stated that muscle fibers of the levator ani muscles and other pelvis floor muscles leave the main muscle and interfere with each other

though anatomically that may be correct, surgically speaking the author never found levator ani muscle fibers crossing the anterior anorectum/rectum or fibers crossing the posterior urethra

and since it is a striated muscle within a fascia the author thinks it strange that separate fibers can leave the muscle, pierce thru the fascia and then cross the midline under neath the urethra or cross the midline in front of the anus and unite

though there may be some connective tissue between the lateral vagina wall and the levator ani muscles, the notion that there is a pubovisceral muscle inserting into the urethra, vagina, perineal body and anus seems far-fetched or is this wishful thinking

attributing paramount functions to a structure that can only function as a wall/floor

due to its circumferential fixation the only thing it can do by contracting is to elevate the perineum outlet diaphragm with sphincter ani as pelvis floor with indirect pushing up/ elevating the endopelvic diaphragm and so contributing to a better configuration of the urine continence mechanism in the female by bringing the mobile posterior urethra wall nearer to the immobile “fixed” anterior urethra wall

so the author fails to understand how the levator ani muscles can play a major role in prevention/development of pelvis organ prolapse and urine intrinsic incontinence

conclusion
the author thinks the attention and the research should be directed towards the corpus intrapelvinum with endopelvic diaphragm by

another concept

the connective tissue body of pelvis as a whole
is responsible for
smooth functioning of the pelvis organs
embedding/protecting the organs with their supply
connecting the organs to the pelvis wall and each other

whilst

the endopelvic diaphragm
is responsible for
stabilizing/securing the pelvis organs
in their variable anatomic position
supporting the continence mechanisms
counteracting
intraabdominal hydrostatic and compression pressure

the pelvis floor structures as a wall are secondary
nothing more and nothing less

first edition august 2007

last edition october 2018

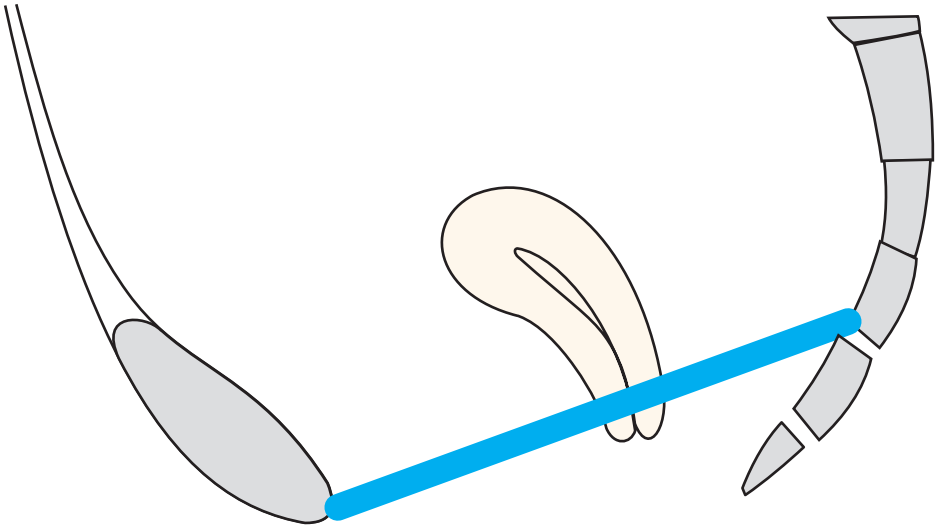

endopelvic diaphragm
smooth muscle
intrinsic myogenic impulses
modulated by autonomic nervous system

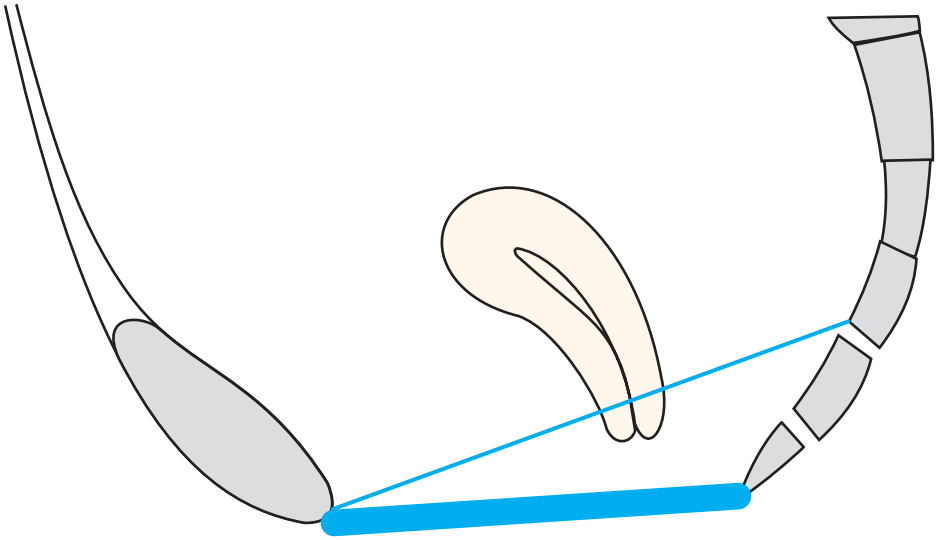

perineum outlet diaphragm = pelvis floor
striated muscle
somatic innervation

postscriptum

this book is the end product of 35 years of struggling in order to understand the basics of what is happening in the female pelvis

returning attention towards the connective tissue body of pelvis

what the author found compelling is

the emperor’s clothes consensus mentality

as influenced by financial impulses from

the medical industry

violating the functional pelvis anatomy
and
the enormous healing power of the human body

and what the author was missing up till today is a real dialogue with other reconstructive pelvis surgeons

even after writing several books the scientific response is minimal which surprised the author in the beginning but now no longer

however, that will not keep the author from continuing publishing his experience, expertise and ideas in book format

abbreviations

vvf	=	vesicovagnal fistula
rvf	=	rectovaginal fistula
uvvf	=	urethrovesicovaginal fistula
vcvf	=	vesicocervicovaginal fistula
vuvf	=	vesicouterovaginal fistula
cx	=	cervix
avw	=	anterior vagina wall
pvw	=	posterior vagina wall
pcmf	=	pubocervical musculofascia
atf	=	arcus tendineus fasciae
atlam	=	arcus tendineus of levator ani muscle
lam	=	levator ani muscle
pcm	=	pubcoccygeus muscle
ocm	=	obturatococcygeus muscle
iscm	=	(ischio)coccygeus muscle
iom	=	obturator internus muscle
pm	=	piriformis muscle
sul	=	sacrouterine ligament
bl	=	broad ligament
cl	=	cardinal ligament
epd	=	endopelvic diaphragm
ch	=	charrière
g	=	gauge
h	=	hegar
p	=	parity
sb	=	stillborn
cs	=	cesarean section
sth	=	subtotal hysterectomy
tah	=	total abdominal hysterectomy
tvh	=	total vaginal hysterectomy

euo	=	external urethra opening
iuo	=	internal urethra opening
uv(-junction)	=	urethrovesical (junction)
euo/f	=	distance between euo and fistula
f/c	=	distance between fistula and cervix
f/v	=	distance between fistula and vagina vault;
euo/b	=	distance between euo and catheter balloon
euo/bw	=	distance between euo and bladder wall (fundus)
a/f	=	distance between anus and (rectovaginal) fistula
i/v	=	distance between introitus and vagina vault; vagina length
pa	=	pubic arch
ap	=	anterior to posterior pelvis diameter
ar	=	anal reflex
gm	=	gastrocnemius muscle
sm	=	soleus muscle
at	=	achilles tendon
min	=	minute
hr	=	hour
wk	=	week
mth	=	month
yr	=	year
R	=	right
L	=	left

bladder capacity by longitudinal diameter (euo/bw minus euo/b)

small	$\leq$ 4 cm
moderate	5-6 cm
normal	7-12 cm
transitional	13-14 cm
increased	$\geq$ 15 cm

normal pelvis measurements

vagina length 10-12 cm

euo/c 6-7-8 cm

anatomic urine continence mechanism 4-5 cm

anatomic stool continence mechanism 4-5 cm

urethra length 3.5-4 cm

however, during surgery it is more in the range of 2.5-3 cm; exceptionally 5 cm

longitudinal bladder diameter (euo/bw minus euo/b) 7-12 cm

anorectum 4-5 cm

symphysis 5-6 cm broad
axis inclination 30-45° as to horizontal in the upright position

pubic arch 85-90°

atf 7.5-8 cm
inclination 25-30° as to horizontal from pubis bone to ischium spine

atlam 7-7.5 cm
inclination 25-30° as to horizontal from pubis bone to ischium spine

angle between symphysis and atf/atlam 110-125°

inter ischium spine distance 10 cm

inter ischium tuberosity distance 10-11 cm

pelvis inlet plane inclination 55-60° to horizontal from superior symphysis edge to promontory in the upright position

pelvis outlet 10-15° to horizontal from inferior symphysis to tip of coccyx in the upright position

anterior triangle pelvis outlet from inferior symphysis to ischium tuberosity in one plane with -10 to-15° inclination to horizontal in upright position

posterior triangle pelvis outlet from ischium tuberosity to tip of coccyx in one plane with 45-50° inclination as to horizontal in upright position

angle anterior perineum/posterior perineum 55-65°/115-125°

pelvis outlet surface 75-80 sq cm

gap between levator ani ledges 25-30 sq cm

diameter recta from inferior symphysis up to tip of coccyx 9-9.5 cm; up to 10.5-11cm during delivery

perineum outlet

spb = symphysis to perineal body	3.5-4.5 cm
pb height	2 cm
anus (+ sphincter) diameter	1.5-2 cm
pac = anus to coccyx bone	5-6 cm

references

ashton-miller j a and delancey j o l
functional anatomy of the female pelvic anatomy ann ny acad sci 2007; 1101: 266-296

barber d b
contemporary views of female pelvic anatomy cleveland clin j med 2005 vol 72 suppl 4 S3-S11

delancey j o l
why do women have stress incontinence neurourol urodyn 2010; 29:s13-s17

delancey jol and ashron-miller j a
pathophysiology of adult urine incontinence gastroenterology 2004; 126: 623-632

gardner e, gray d j, o'rahilly r
anatomy; a regional study of human structure saunders 1975

hafferl a
lehrbuch der topographischen anatomie springer verlag 1957

halban j and talbert j
anatomie und aetiologe der genitalprolapse beim weibe wilhelm braumüller, 1907

hoyte l and damaser m
biomechanics of the female pelvic floor elsevier 2016

lahodny j
vaginale inkontinenz- und deszensuschirurgie ferdinand enke verlag stuttgart 1991

marani e and koch wfrm
the pelvis: structure, gender and society springer verlag 2014

martius h
die gynäkologischen operationen und ihre topographisch-anatomischen grundlagen georg thieme verlag 1960

waaldijk k
obstetric fistula surgery; art and science; the basics printmarkt.eu 2008

waaldijk k
25,000 obstetric trauma procedures as covered by 30 annual evaluation reports

waaldijk k
obstetric trauma surgery; art and science; sphincter ani rupture printmarkt.eu 2015

and as influenced by many others since the author started his medicine study in 1959 but especially by prof j m greep, prof t k a b eskes and dr med h stenkhoff

hard copies
to be ordered from
as
printed by:

Printmarkt.eu
Dé regionale print-, design- en communicatiestudio

info@printmarkt.eu
www.printmarkt.eu

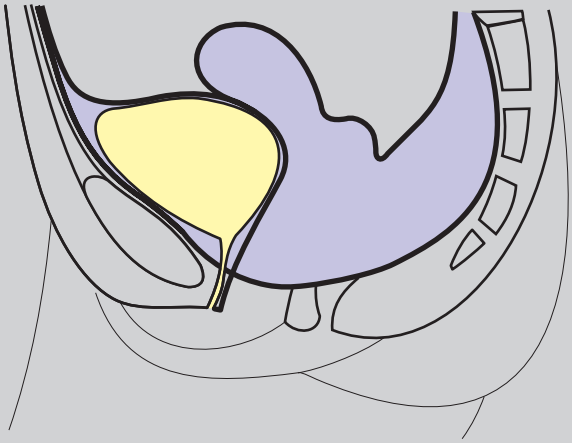

anterior pre/subperitoneal compartment
urinary tract

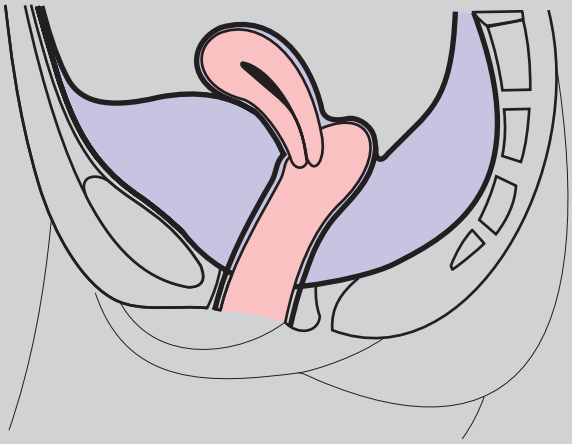

median subperitoneal compartment
genital tract

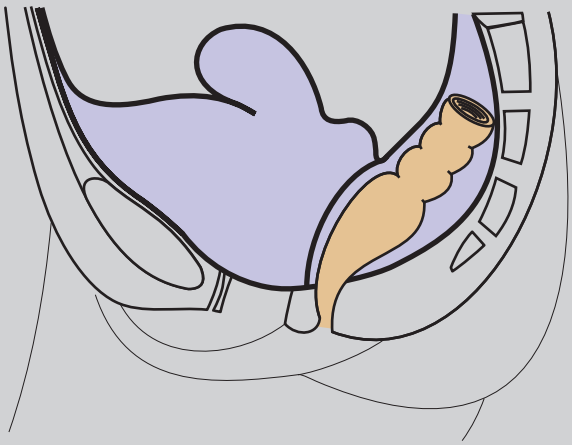

posterior sub/retroperitoneal compartment
digestive tract